

Chronic subdural hematoma in a child with acute myeloid leukemia after leukocytosis

Mehmet Basmaci, Askin E. Hasturk

Abstract

Severe complications that develop in the early stages in patients with acute leukemia have a mortal course. Bleeding, leukostasis, and less frequently, infections are responsible for early mortality. Hemorrhage is most common in acute leukemia and usually leads to death. Hemorrhage may occur due to chemotherapy or bone marrow transplantation in patients with acute leukemia. Leukocytosis, thrombocytopenia, sepsis, and coagulopathy increase the risk of bleeding. There may be multiple etiologic factors. Subdural or subarachnoid hemorrhage is less common than an intra-axial hemorrhage. The incidence of spontaneous subdural hematoma is higher in patients with leukemia. Although advances in the treatment of platelet transfusion and disseminated intravascular coagulation have decreased the incidence of hemorrhagic complications in patients receiving chemotherapy for acute leukemia, intracranial hemorrhage-related deaths are a significant problem. We discussed the etiology and management of chronic subdural hematoma detected in a two-year-old male patient with Acute Myeloid Leukemia and hyperleukocytosis.

Keywords: Acute myeloid leukemia, child, leukocytosis, subdural hematoma

Access this article online

Website: www.ijccm.org

DOI: 10.4103/0972-5229.106508

Quick Response Code:



Introduction

Hemorrhage may occur due to chemotherapy or bone marrow transplantation in patients with acute leukemia. Leukocytosis, thrombocytopenia, sepsis, and coagulopathy increase the risk of bleeding.^[1-3] Disseminated intravascular coagulation also occurs in patients with leukemia due to hypofibrinogenemia.^[1,3] Subdural or subarachnoid hemorrhage is less common than an intra-axial hemorrhage. Hemorrhage is most common in acute leukemia and usually leads to death.^[3-5] Hemorrhage can be seen in patients with fulminant leukocytosis (blast crisis), typically involving a white blood cell count above 300,000/mm³ and leukostasis. Platelet counts less than 10,000/mm³

and drugs such as L-asparaginase or prednisone may increase the risk of bleeding.^[5-7]

Case Report

The two-year-old patient, who was followed up by the hematology department with the diagnosis of acute myeloid leukemia, was referred because of seizure, vomiting, and agitation. The patient, who had confusion, underwent emergency brain-computed tomography. A chronic subdural hematoma extending from the left frontal region to the occipital subdural region, which was 4 cm at its thickest, was detected [Figure 1]. The white blood cell count was 157,000/mm³, and platelet count was 48,000/mm³ as determined by complete blood count. There was no history of head injury or trauma. The patient was operated on urgently basis with the current findings. The hematoma was evacuated with left parietal craniotomy and was observed to have high pressure. After the surgery, a dramatic improvement was seen in the patient's neurological status. The hematoma was seen to be evacuated in control CT [Figure 2]. The patient was transferred to the hematology department for the remainder of the leukemia treatment.

From:

Department of Neurosurgery, Dr. Abdurrahman Yurtaslan Oncology Training and Research Hospital, Ankara, Turkey

Correspondence:

Askin Esen Hasturk, Department of Neurosurgery, Dr. Abdurrahman Yurtaslan Oncology Training and Research Hospital, Vatan Caddesi, 06200, Demetevler, Ankara, Turkey.
E-mail: aehasturk@yahoo.com

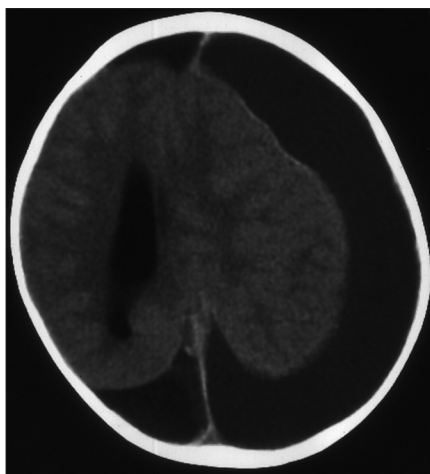


Figure 1: Leukemic leukocytosis in a two-year-old boy who presented with vomiting and progressive lethargy. Hyperleukocytosis (white blood cell count of 157,000/mm³) and thrombocytopenia (platelet count of 48,000/mm³) were significant laboratory parameters. The axial computed tomographic (CT) scan reveals a fronto-occipital subdural hematoma

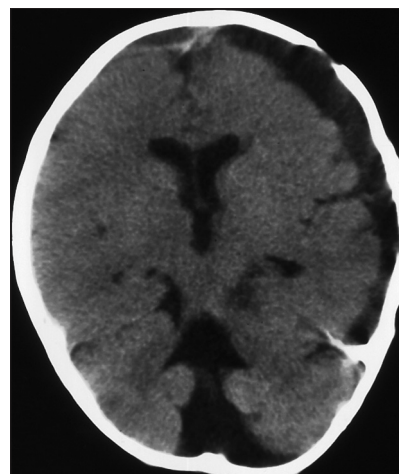


Figure 2: A postoperative axial CT shows adequate evacuation of the subdural hematoma

Discussion

A significant number of patients with acute leukemia die due to severe complications that develop in early stages. The incidence of tumor-related subdural hematoma is 0.5-4%. This incidence is higher in cancers such as leukemia.^[3,6,8] Factors such as head trauma, chemotherapy, and coagulopathy increase the risk of bleeding. The incidence of spontaneous subdural hematoma is higher in patients with leukemia. Hemorrhage can be seen due to occlusion of the blood brain barrier by tumor cells, chemotherapy-induced thrombocytopenia, disseminated intravascular coagulation, and leukocytosis. There may be multiple etiologic factors.^[2,6,9] Hyperleukocytosis is seen in 5-8% of patients with acute leukemia at diagnosis. Although hyperleukocytosis can be seen in all acute leukemias, it is more frequently seen in childhood acute lymphoblastic leukemia (ALL), adult myelomonocytic (M4), and monoblastic leukemias (M5).^[3,5,8,10] Leukostasis is a clinical syndrome with a progressive and mortal course and generates 20% to 40% of the causes of early-stage mortality in acute leukemia patients.^[5,7,9,11] The most common causes of death caused by leukostasis are intracranial hemorrhage and respiratory failure. Hydration, urine alkalinization, allopurinol treatment, and leukopheresis are applied to prevent or reduce hyperleukocytosis-associated metabolic and vascular complications. Leukopheresis can quickly reduce the number of leukocytes over a short period of time and manage the leukostasis-related clinical signs.^[5,7,10,12] Current treatment includes emergency intravenous fluids, administration of allopurinol and chemotherapy, and aggressive correction of coagulopathy and thrombocytopenia.^[5,7,11]

Seizure, altered mental status, focal neurological deficits, irritability, lethargy, and bulging fontanel in children under 2 years of age are common. Sometimes, the condition can be detected incidentally without clinical symptoms.^[2,3,6,8] Our patient also had complaints of agitation, vomiting, and confusion. A brain CT was taken following these complaints of our patient, and the chronic subdural hematoma was identified. The patient, who also had respiratory distress and disorder, was diagnosed with leukostasis based on white blood cell count. Notably, the development of chronic subdural hematoma is multifactorial in the pediatric population. Advanced neuro-imaging techniques are important for early diagnosis and treatment. Contrast-enhanced or non-enhanced cranial CT is diagnostic. Subdural collections could occur bilaterally at the rate of 50%. An MRI is important in detecting parenchymal compression, and the amount and formation time of subdural hemorrhage. However, it is not important for the decision about surgery. Emergency CT is valuable for diagnosis.^[4,8,12]

The main treatment modalities for the irrigation of bleeding include the following: Burr hole, subdural taps, subdural drainage, and subdural peritoneal shunt. Subdural hematoma with neurological deficits may be evacuated by craniotomy. Drainage of a chronic subdural hematoma was required in a child with acute leukemia where chronic subdural collection caused neurologic impairment while the patient was undergoing chemotherapy.^[2,5,10,11] Leukopheresis could not be applied to our patient, but steroids were applied following adequate hydration, and hydroxyurea and allopurinol were initiated. Fresh-frozen plasma was administered to prevent coagulopathy, which frequently develops during the course of acute hyperleukocytic leukemia. The subdural hematoma was evacuated with craniotomy.

The pressure on parenchymal tissue was observed to be relieved after the evacuation of hematoma.

Hemorrhagic complications in patients with leukemia have a high rate of mortality and morbidity. 40% of cytotoxic chemotherapy-induced intracranial hemorrhages are fatal. Bleeding, leukostasis, and less likely, infections are responsible for mortality at this early stage.^[3,6,9,11]

References

1. Humphries JE, Hess CE, Stewart FM. Acute promyelocytic leukemia: Impact of hemorrhagic complications on response to induction chemotherapy and survival. *South Med J* 1990;83:1157-61.
2. Barbui T, Falanga A. Disseminated intravascular coagulation in acute leukemia. *Semin Thromb Hemost* 2001;27:593-604.
3. Comănescu A, Roșca E, Bota M, Ninulescu G. Chronic subdural hematoma in a patient with acute myeloid leukemia and dural metastatic infiltration. *Rom J Morphol Embryol* 2008;49:259-62.
4. Chen CY, Zimmerman RA, Faro S, Bilaniuk LT, Chou TY, Molloy PT. Childhood leukemia: Centralnervous system abnormalities during and after treatment. *AJNR Am J Neuroradiol* 1996;17:295-310.
5. Wurthner JU, Kohler G, Behringer D, Lindemann A, Mertelsmann R, Lubbert M. Leukostasis followed by hemorrhage complicating the initiation of chemotherapy in patients with acute myeloid leukemia and hyperleukocytosis: A clinicopathologic report of four cases. *Cancer* 1999;85:368-74.
6. Lin CH, Hung GY, Chang CY, Chien JC. Subdural hemorrhage in a child with acute promyelocytic leukemia presenting as subtle headache. *J Chin Med Assoc* 2005;68:437-40.
7. Thiebaut A, Thomas X, Belhabri A, Anglaret B, Archimbaud E. Impact of preinduction therapy leukapheresis on treatment outcome in adult acute myelogenous leukemia presenting with hyperleukocytosis. *Ann Hematol* 2000;79:501-6.
8. Abdulhamid MM, Li YM, Hall WA. Spontaneous acute subdural hematoma as the initial manifestation of chronic myeloid leukemia. *J Neurooncol* 2011;101:513-6.
9. Eguiguren JM, Schell MJ, Crist WM, Kunkel K, Rivera GK. Complications and outcome in childhood acute lymphoblastic leukemia with hyperleukocytosis. *Blood* 1992;79:871-5.
10. Poreu P, Cripe LD, Ng EW, Bhatia S, Danielson CM, Orazi A, *et al.* Hyperleukocytic leukemias: A review of pathophysiology, clinical presentation and management. *Leuk Lymphoma* 2000;39:1-18.
11. Maurer HS, Steinherz PG, Gaynon PS, Finklestein JZ, Sather HN, Reaman GH, *et al.* The effect of the initial management of hyperleukocytosis on early complications and outcome of children with acute lymphoblastic leukemia. *J Clin Oncol* 1988;6:1425-32.
12. Bromberg JE, Vandertop WP, Jansen GH. Recurrent subdural haematoma as the primary and sole manifestation of chronic lymphocytic leukaemia. *Br J Neurosurg* 1998;12:373-6.

How to cite this article: Basmaci M, Hasturk AE. Chronic subdural hematoma in a child with acute myeloid leukemia after leukocytosis. *Indian J Crit Care Med* 2012;16:222-4.

Source of Support: Nil, **Conflict of Interest:** None declared.

Announcement

Android App



Download
**iPhone, iPad
application**

FREE

A free application to browse and search the journal's content is now available for Android based mobiles and devices. The application provides "Table of Contents" of the latest issues, which are stored on the device for future offline browsing. Internet connection is required to access the back issues and search facility. The application is compatible with all the versions of Android. The application can be downloaded from <https://market.android.com/details?id=comm.app.medknow>. For suggestions and comments do write back to us.