

# Paraquat - A deadly poison: Report of a case and review

Kavitha Saravu, Sonal Sekhar<sup>1</sup>, Ananth Pai<sup>2</sup>, Ananthakrishna Shastry Barkur, V. Rajesh<sup>1</sup>, Jagadeswara Rao Earla<sup>1</sup>

## Abstract

Paraquat is a bipyridilium herbicide used widely in our country and is a highly toxic compound. A 16-year-old female patient was admitted to the emergency department of our tertiary care hospital in South India with the history of alleged consumption of paraquat poison. Since there is dearth of high quality evidence-based treatment for this poisoning, different treatment modalities have been tried to manage patient's condition. In this case, none of the strategies could work well. Most of the patients reported with paraquat intoxication are from agricultural background; usually such patients cannot afford the treatment expenses. This paper presents a fatal case of acute poisoning with paraquat who succumbed to acute respiratory distress syndrome (ARDS).

**Keywords:** Acute respiratory distress syndrome, case study, clinical toxicology, herbicide, paraquat, pesticide poisoning

## Access this article online

Website: [www.ijccm.org](http://www.ijccm.org)

DOI: 10.4103/0972-5229.117074

Quick Response Code:



## Introduction

Paraquat, a toxic bipyridyl herbicide, is a bright green corrosive liquid with pungent smell. Its herbicidal properties were discovered in 1950s and first marketed in 1962. Once, it was encouraged by US for usage in Mexico to abolish marijuana plants. Presently, it is the second highest-selling weed killer globally and is available in a 20% solution form and that needs to be diluted before agricultural use.<sup>[1]</sup> Usually, adult cases of intoxication are due to suicidal attempts instead of homicidal or accidental exposure. The main acute systemic effects are pulmonary edema, convulsions, cardiac, renal, and hepatic failure.<sup>[2]</sup> The LD<sub>50</sub> in humans is approximately 35 mg/kg, which translates into as little as 10-15 ml of a 20% solution. This paper represents a case of acute poisoning with paraquat and detailed review of the intoxication.

## Case Report

A 16-year-old female patient was admitted to emergency department of our tertiary care hospital with history of alleged consumption of paraquat poison, 13 days before at 19.00 hours at her residence due to failure in matriculation examination. History revealed that after consumption of the poison, she was taken to the local hospital after ½ an hour. Meanwhile, she was reported to have 6 episodes of vomiting. She was treated conservatively; gastric lavage followed by activated charcoal 1 gm/kg was given as an adsorbent and discharged after 6 days from a local hospital. Since then, she was suffering from fever and cough without shortness of breath, orthopnea, chest, and abdominal pain. After 1 week at 21.00 hours, she was brought to our hospital. Her O<sub>2</sub> saturation was 40% on room air, pulse rate was 78 beats/minute, respiratory rate 28 beats/minute, and blood pressure was 100/60 mmHg. Respiratory examination revealed bilateral crepitation. Patient was administered O<sub>2</sub> by 60% venturi, and her saturation picked up to 95%.

Laboratory tests showed leukocytosis, neutrophilia, elevated ESR, and metabolic acidosis with normal renal and liver function. On the second day, she was shifted to ICU due to increasing breathlessness. Empirical

## From:

Departments of General Medicine, <sup>2</sup>Medical Oncology, Kasturba Hospital, Manipal University, <sup>1</sup>Pharmacy Practice, Manipal College of Pharmaceutical Sciences, Manipal, Karnataka, India

## Correspondence:

Mr. Sonal Sekhar, Department of Pharmacy Practice, Manipal College of Pharmaceutical Sciences, Manipal University, Manipal, Karnataka - 576 104, India. E-mail: [sonalsekhar@gmail.com](mailto:sonalsekhar@gmail.com)

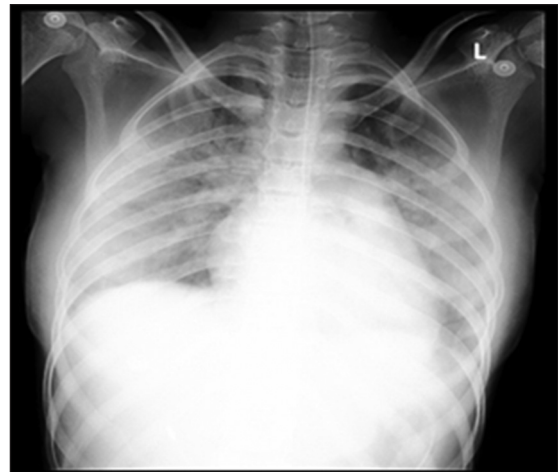antibiotic therapy was started with intravenous piperacillin-tazobactam 4.5 gm stat and continued 8<sup>th</sup> hourly. Antioxidant therapy was initiated on the same day with vitamin E and C. Detoxifying agent N-Acetyl cysteine 600 mg was given orally thrice-daily from second day onwards. In view of persistence hypoxia, she was intubated and put on mechanical ventilator on the 3<sup>rd</sup> day. Midazolam and Morphine were started on same day and continued for 1 week. She was treated with oral cyclophosphamide 50 mg once-daily on 3<sup>rd</sup> day till 12<sup>th</sup> day, and steroid dexamethasone 4 mg i.v. 6 hourly was started on 6<sup>th</sup> day and stopped after one week. Subsequently, she was treated with linezolid and piperacillin-tazobactam when she developed ventilator-associated pneumonia (VAP). Piperacillin-tazobactam was changed to cefoperazone-sulbactam based on culture and sensitivity of endotracheal aspirate, which grew *Klebsiella pneumoniae* and *Acinetobacters* species. The serial chest X-rays done are shown in the Figures 1-3. Patient could not afford to continue the treatment; hence, she was discharged against medical advice in a critical condition.

## Discussion

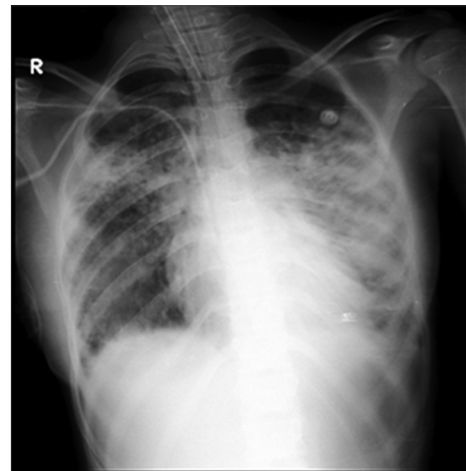
Since bipyridyl salts are caustic, the gastrointestinal tract can be severely injured after ingestion of a concentrated solution.<sup>[3]</sup> Once large concentration of this poison accumulates in lungs or renal cells, it leads to generation of toxic reactive oxygen species through redox cycling, which devastate cellular defensive system. Renal failure can result due to the direct toxicity and hemodynamic changes. Conservation of renal function is vital to reduce plasma paraquat levels and thereby reduce accumulation in lung cells.<sup>[3]</sup>

Symptoms of paraquat ingestion are usually dose-dependent, and intoxication can be categorized to mild, moderate, and fulminant. Mild intoxication can happen with doses  $\leq 20$  mg/kg, which usually produce minor gastrointestinal problems like transient vomiting, diarrhea, and oropharyngeal burns, but usually complete recovery is possible. Moderate intoxication can occur with doses between  $>20$  mg/kg and  $<50$  mg/kg of the poison. Patient may suffer lung injury, pulmonary fibrosis, acute renal failure, and in majority of cases, death occurs within 2-3 weeks. Fulminant intoxication of  $\geq 50$  mg/kg of the poison, may lead to death within 3 days, because of multiple organ failure. In patients who survive longer, fibrotic changes in the alveoli result in gas exchange interference in the lungs and may progress to ARDS.<sup>[3,4]</sup>

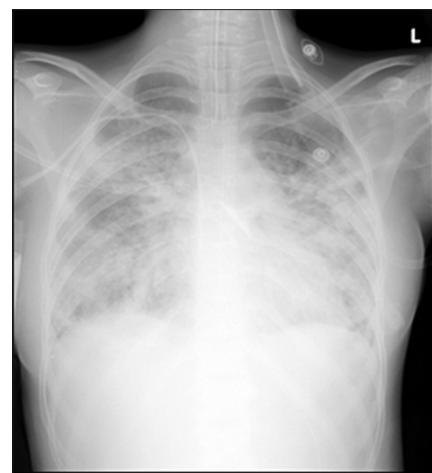Diagnosis of paraquat poisoning is usually made based on circumstantial evidences. It is always important to identify ingested amount of substance as specifically as



**Figure 1:** Bilateral diffuse alveolar shadows predominantly in mid and lower zone



**Figure 2:** Diffuse alveolar shadows predominantly on left side



**Figure 3:** Intensity of bilateral shadow increased (typical ARDS picture)

possible, which is unavailable in this patient. Urinary paraquat concentrations of  $<1$  mg/L within 24 hours of toxicity have a high probability of survival.<sup>[5-7]</sup> Since patient reported to us after 13 days of ingestion, data

regarding serum and urine levels at specific time points is lacking. We did not confirm the presence of paraquat by using dithionite test in urine or plasma. In our patient, the clinical history, presentation, and documentation of paraquat consumption endorses the diagnosis positive. Based on the data of survivors and non-survivors from the Indian study, delayed hospital referral, incidence of hepatic, respiratory, circulatory, or multi-organ failure were significantly related to mortality. The comparative data between the non-survivors and the patients who took discharge against medical advice showed no significant difference.<sup>[6]</sup>

Conventional treatment includes nasogastric tube fixation, gastric lavage with normal saline, charcoal-sorbitol lavage, forced alkalinized diuresis and hemodialysis or hemoperfusion. Hemoperfusion with activated charcoal is effective if initiated within 4 hours of paraquat intoxication. Since the patient reported after few days, benefit was not expected from this in our patient.<sup>[6]</sup> Paraquat accumulation in lung tissues exerts a destructive effect, leading to hypoxemia, requiring mechanical ventilation. Ironically, oxygen supplementation may have a deleterious effect because it increases the number of toxic radicals. Oxygen should, therefore, be given only to correct hypoxemia.<sup>[1]</sup> Subsequent management includes antibiotics for supervening infection, supporting renal function with hemodialysis or filtration. Potent analgesics such as opiates may be required to alleviate intense pain from gastrointestinal tract injury, ulceration, and inflammation. Some antioxidants like vitamins C and E have been clinically used to protect against free-radical toxicity. N-acetyl cysteine is also used as an antioxidant because of its free radical scavenging property, and it will increase intracellular glutathione levels. Thereby, it will provide protective effect on lung parenchymal cells.<sup>[3-4]</sup>

In a study by Lin *et al.*, therapeutic effect has been reported with high dose cyclophosphamide and glucocorticoid where survival is about 75%.<sup>[8]</sup> An intensive care unit study and a meta-analysis conducted by Agarwal *et al.*, concluded that immunosuppressive therapy with cyclophosphamide and glucocorticoids have potential role in management of paraquat poisoning in moderate to severe poisoning cases.<sup>[9,10]</sup> Since there is lack of clear evidence-based therapy for paraquat intoxication, different approaches have been tried for supportive management. In the present case, our therapeutic stratagems did not improve patient's clinical condition.

## Conclusion

The data on paraquat poisoning from our country is scanty. We report our experience of acute paraquat poisoning with ARDS. The unexplained combination of gastrointestinal symptoms, acute renal injury, and respiratory failure must be suspected of paraquat toxicity, even in the absence of ingestion history. Both urine and serum concentrations of samples at known time intervals post-ingestion are to be determined for assessing severity of the intoxication and to predict survival chance. If patient presents early, the therapeutic interventions with hemoperfusion and dialysis is recommended to prevent pulmonary and multi-organ failure. We did not find any significant benefits for the cyclophosphamide-dexamethasone regimen.

## Acknowledgment

We express our gratitude to KMC Hospital, Manipal University and Manipal College of Pharmaceutical Sciences for the support. We also thank to Dr. Sisira M, Senior Resident, Calicut Medical College for the valuable guidance.

## References

1. Arts J, Schuit G, Schipper A, Kleij van der B. A case report of paraquat poisoning. *Eur J Hosp Pharm* 2006;12:22-4.
2. Chen HW, Tseng TK, Ding LW. Intravenous paraquat poisoning. *J Chin Med Assoc* 2009;72:547-50.
3. Dinis-Oliveira RJ, Duarte JA, Sánchez-Navarro A, Remião F, Bastos ML, Carvalho F. Paraquat poisonings: Mechanisms of lung toxicity, clinical features, and treatment. *Crit Rev Toxicol* 2008;38:13-71.
4. Dinis-Oliveira RJ, Sarmento A, Reis P, Amaro A, Remiao F, Bastos ML, *et al.* Acute paraquat poisoning: Report of a survival case following intake of a potential lethal dose. *Pediatr Emerg Care* 2006;22:537-40.
5. Soloukides A, Moutzouris DA, Kassimatis T, Metaxatos G, Hadjiconstantinou V. A fatal case of paraquat poisoning following minimal dermal exposure. *Ren Fail* 2007;29:375-7.
6. Sandhu JS, Dhiman A, Mahajan R, Sandhu P. Outcome of paraquat poisoning - a five year study. *Indian J Nephrol* 2003;13:64-8.
7. Botella de Maglia J, Belenguer Tarín JE. Paraquat poisoning. A study of 29 cases and evaluation of the effectiveness of the Caribbean scheme. *Med Clin (Bare)* 2000;115:530-3.
8. Afzali S, Gholyaf M. The Effectiveness of Combined Treatment with Methylprednisolone and Cyclophosphamide in Oral Paraquat Poisoning. *Arch Iranian Med* 2008;11:387-91.
9. Agarwal R, Srinivas R, Aggarwal AN, Gupta D. Experience with paraquat poisoning in a respiratory intensive care unit in North India. *Singapore Med J* 2006;47:1033-7.
10. Agarwal R, Srinivas R, Aggarwal AN, Gupta D. Immunosuppressive therapy in lung injury due to Paraquat poisoning: A meta-analysis. *Singapore Med J* 2007;48:1000-5.

**How to cite this article:** Saravu K, Sekhar S, Pai A, Barkur AS, Rajesh V, Earla JR. Paraquat - A deadly poison: Report of a case and review. *Indian J Crit Care Med* 2013;17:182-4.

**Source of Support:** Nil, **Conflict of Interest:** None declared.