

# Apnea testing with continuous positive airway pressure for the diagnosis of brain death in a patient with poor baseline oxygenation status

Gentle Sunder Shrestha, Pramesh Sunder Shrestha, Subhash Prasad Acharya, Gopal Sedain<sup>1</sup>, Sandip Bhandari, Diptesh Aryal, Bikram Gajurel<sup>2</sup>, Moda Nath Marhatta, Roshana Amatya

## Abstract

Apnea testing is a key component in the clinical diagnosis of brain death. Patients with poor baseline oxygenation may not tolerate the standard 8-10 min apnea testing with oxygen insufflation through tracheal tube. No studies have assessed the safety and feasibility of other methods of oxygenation during apnea testing in these types of patients. Here, we safely performed apnea testing in a patient with baseline PaO<sub>2</sub> of 99.1 mm Hg at 100% oxygen. We used continuous positive airway pressure (CPAP) of 10 cm of H<sub>2</sub>O and 100% oxygen at the flow rate of 12 L/min using the circle system of anesthesia machine. After 10 min of apnea testing, PaO<sub>2</sub> decreased to 75.7 mm Hg. There was a significant rise in PaCO<sub>2</sub> and fall in pH, but without hemodynamic instability, arrhythmias, or desaturation. Thus, the apnea test was declared positive. CPAP can be a valuable, feasible and safe means of oxygenation during apnea testing in patients with poor baseline oxygenation, thus avoiding the need for ancillary tests.

**Keywords:** Apnea test, brain death, poor baseline oxygenation

### Access this article online

Website: [www.ijccm.org](http://www.ijccm.org)

DOI: 10.4103/0972-5229.132510

### Quick Response Code:



## Introduction

Brain death is defined as the irreversible loss of the capacity for consciousness combined with the irreversible loss of all brainstem functions, including the capacity to breathe.<sup>[1]</sup> Apnea test is a key component in the clinical diagnosis of brain death. PaO<sub>2</sub> > 200 mm Hg after 10 min of preoxygenation with 100% oxygen is necessary for performing apnea test. To preserve oxygenation during apnea test, it is recommended to place an insufflation catheter through the endotracheal tube close to the level of the carina.<sup>[2]</sup> Test is aborted if oxygen saturation measured by pulse oxymetry is <85% for >30 s. Inadequate pretest oxygenation has previously

been associated with failed completion of apnea testing.<sup>[3]</sup> Oxygenation was shown to be best maintained with continuous positive airway pressure (CPAP) system when compared with oxygen insufflation method or T-piece system.<sup>[4]</sup> No studies have assessed the safety and feasibility of other methods of oxygenation during apnea testing in patients with poor baseline oxygenation status. Here, we safely performed apnea test using CPAP of 10 cm of H<sub>2</sub>O in a patient with baseline PaO<sub>2</sub> of 99.1 mm Hg at 100% oxygen. To the best of our knowledge, there is only one reported case of apnea test performed in patient with acute respiratory distress syndrome. A commercially available valve was used to apply CPAP.<sup>[5]</sup> For the 1<sup>st</sup> time, we have mentioned the use of anesthesia machine circle system for applying CPAP during apnea test.

## Case Report

A 40-year-old male patient presented to hospital emergency 4 h after gunshot injury to right temporal region. On arrival, he was pulseless. After 30 min of cardiopulmonary resuscitation with repeated cycles

### From:

Department of Anaesthesiology, <sup>1</sup>Department of Surgery, Neurosurgery Unit, <sup>2</sup>Department of Neurology, Institute of Medicine, Tribhuvan University Teaching Hospital, Maharajgunj, Kathmandu, Nepal

### Correspondence:

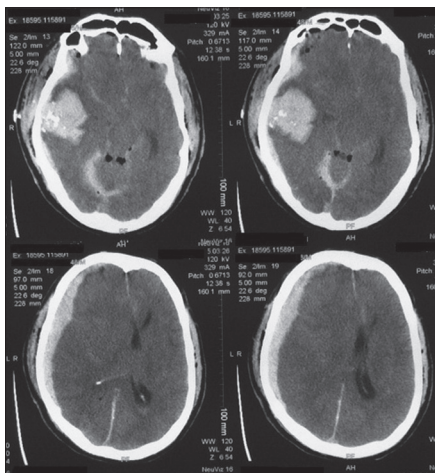
Dr. Gentle Sunder Shrestha, Department of Anaesthesiology, Institute of Medicine, Tribhuvan University Teaching Hospital, Maharajgunj, Kathmandu, Nepal.  
E-mail: [gentlesunder@hotmail.com](mailto:gentlesunder@hotmail.com)

of adrenaline, return of spontaneous circulation was attained. Airway was secured with an endotracheal tube. Patient required noradrenaline infusion to maintain blood pressure. Computed tomography scan of the head revealed right temporal intraparenchymal hematoma and subdural hematoma with mass effect [Figure 1]. Patient underwent emergency craniotomy for evacuation of clot. Neurological status of the patient remained poor with Glasgow coma scale of 2/10 (intubated) even after 2 days off sedation and paralyzing agents. Pupils were bilaterally 4 mm in size with no response to bright light. Corneal, pharyngeal and gag reflexes were absent. Oculovestibular reflex was absent. Oculocephalic reflex was not performed due to the presence of a cervical collar. Patient was euvolemic, with nasopharyngeal temperature of 37.4°C. Systolic blood pressure was maintained >100 mm Hg with noradrenaline infusion at 0.2 µg/kg/min and vasopressin infusion at 0.03 units/min.

Apnea test was planned. After ventilating the patient for 10 min with 100% oxygen, his baseline arterial blood gas (ABG) revealed pH of 7.36, PaCO<sub>2</sub> of 43.3 mm Hg and PaO<sub>2</sub> of 99.1 mm Hg. Apnea test was performed with CPAP of 10 cm of H<sub>2</sub>O and 100% oxygen at the flow rate of 12 L/min using Kimura Siesta 21 – PS anesthesia machine as shown in Figure 2. The circle system with reservoir bag was used and adjustable pressure limiting valve was manually adjusted to generate a constant CPAP of 10 cm of H<sub>2</sub>O as shown by the manometer. No respiratory movements were noticed during 10 min of apnea testing. There was no hemodynamic instability, arrhythmias or desaturation. Lowest oxygen saturation recorded by pulse oxymeter was 89%. ABG at the end of 10 min showed pH of 7.14 with PaCO<sub>2</sub> of 75.3 mm Hg and PaO<sub>2</sub> of 75.7 mm Hg. Apnea test was positive and the patient was declared brain dead.

## Discussion

Apnea test is one of the main steps in neurological determination of death. The test is considered positive if respiratory movements are absent and arterial PaCO<sub>2</sub> is ≥60 mm Hg (or 20 mm Hg increase over baseline normal PaCO<sub>2</sub>). Test needs to be aborted if systolic blood pressure decreases to <90 mm Hg or if patient develops significant arrhythmias or if there is significant oxygen desaturation. After preoxygenating with 100% oxygen for 10 min, it is recommended to insufflate 100% oxygen at 6 L/min through the endotracheal tube, using a catheter, to preserve oxygenation.<sup>[2]</sup> This method of oxygenation is not free of risk as there are reports of tension pneumothorax leading to cardiac arrest when apnea test was performed.<sup>[6]</sup> In a study, comparing three oxygenation systems, application of 10 cm of H<sub>2</sub>O of CPAP at 100% oxygen flow of 12 L/min was shown to decrease PaO<sub>2</sub> by 22.4 ± 76 mm Hg as compared to 99.1 ± 158 mm Hg with oxygen insufflation method and 91.6 ± 133 mm Hg with T-piece system after 10 min. The findings were consistent with that in our patient where PaO<sub>2</sub> decreased by 23.4 mm Hg at the end of 10 min. In a case report by Hocker *et al.*, apnea test was successfully performed in a patient with severe acute respiratory distress syndrome after applying a lung recruitment maneuver. CPAP of 20 cm of H<sub>2</sub>O was applied during the test.<sup>[5]</sup> Our patient was on two vasopressors and hypotension is common during lung recruitment maneuver<sup>[7]</sup> and also during apnea test itself.<sup>[8]</sup> The maneuver was also shown to have adverse effects on cerebral hemodynamics and metabolism in patients with cerebral injury.<sup>[9]</sup> Hence, we didn't perform lung recruitment maneuver. At the end of 10 min of test, PaCO<sub>2</sub> reached 75.3 mm Hg, with a rise of 32 mm Hg from baseline. The rise was consistent with the findings of Frumin *et al.*, where they found an average rise of 3 mm Hg/min of apneic oxygenation.<sup>[10]</sup> Arterial pH dropped to



**Figure 1:** Computed tomography scan of head showing right intraparenchymal and subdural hematoma with mass effect



**Figure 2:** Circle system of anesthesia machine with reservoir bag, used to generate constant continuous positive airway pressure of 10 cm of H<sub>2</sub>O

7.14. Criteria for a positive test were met and the patient was declared brain dead.

Continuous positive airway pressure valve, as used in the case report by Hocker *et al.*, is not readily available in resource limited places. All the modern intensive care unit ventilators have apnea backup ventilation in CPAP mode, making it not feasible during apnea testing. For the first time in medical literature, we are reporting the use of an anesthesia machine circle system for application of CPAP during apnea test. It is simple to perform, is easily available and adds no financial burden to the patient. Application of lung protective strategy with low tidal volume ventilation and use of CPAP during apnea test in potential organ donors with beating heart increased the number of eligible and harvested lungs when compared with conventional ventilatory strategy with apnea test performed by disconnecting the ventilator.<sup>[11]</sup>

Ancillary tests cannot replace neurological examination and there is potential for false positive results.<sup>[2]</sup> In this patient, application of CPAP during apnea test helped to avoid ancillary tests. Performance of ancillary tests would require transport of this hemodynamically unstable patient with poor baseline oxygenation to radiology suit. Moreover, these tests are not readily available in resource constrained countries like ours.

Continuous positive airway pressure can be a valuable, feasible, and safe means of oxygenation during apnea testing in patients with poor baseline oxygenation, thus avoiding the need for ancillary tests. There is a need for randomized studies to evaluate the safety and feasibility of apnea test using CPAP in patients with poor baseline oxygenation status.

## References

1. Shemie SD, Doig C, Dickens B, Byrne P, Wheelock B, Ricker G, *et al.* Severe brain injury to neurological determination of death: Canadian forum recommendations. *CMAJ* 2006;174:S1-13.
2. Wijdiels EF, Varelas PN, Gronseth GS, Greer DM, American Academy of Neurology. Evidence-based guideline update: Determining brain death in adults: Report of the Quality Standards Subcommittee of the American Academy of Neurology. *Neurology* 2010;74:1911-8.
3. Goudreau JL, Wijdiels EF, Emery SF. Complications during apnea testing in the determination of brain death: Predisposing factors. *Neurology* 2000;55:1045-8.
4. Lévesque S, Lessard MR, Nicole PC, Langevin S, LeBlanc F, Lauzier F, *et al.* Efficacy of a T-piece system and a continuous positive airway pressure system for apnea testing in the diagnosis of brain death. *Crit Care Med* 2006;34:2213-6.
5. Hocker S, Whalen F, Wijdiels EF. Apnea testing for brain death in severe acute respiratory distress syndrome: A possible solution. *Neurocrit Care* 2014;20:298-300.
6. Bar-Joseph G, Bar-Lavie Y, Zonis Z. Tension pneumothorax during apnea testing for the determination of brain death. *Anesthesiology* 1998;89:1250-1.
7. Grasso S, Mascia L, Del Turco M, Malacarne P, Giunta F, Brochard L, *et al.* Effects of recruiting maneuvers in patients with acute respiratory distress syndrome ventilated with protective ventilatory strategy. *Anesthesiology* 2002;96:795-802.
8. Jeret JS, Benjamin JL. Risk of hypotension during apnea testing. *Arch Neurol* 1994;51:595-9.
9. Bein T, Kuhr LP, Bele S, Ploner F, Keyl C, Taeger K. Lung recruitment maneuver in patients with cerebral injury: Effects on intracranial pressure and cerebral metabolism. *Intensive Care Med* 2002;28:554-8.
10. Frumin MJ, Epstein RM, Cohen G. Apneic oxygenation in man. *Anesthesiology* 1959;20:789-98.
11. Mascia L, Pasero D, Slutsky AS, Arguis MJ, Berardino M, Grasso S, *et al.* Effect of a lung protective strategy for organ donors on eligibility and availability of lungs for transplantation: A randomized controlled trial. *JAMA* 2010;304:2620-7.

**How to cite this article:** Shrestha GS, Shrestha PS, Acharya SP, Sedain G, Bhandari S, Aryal D, Gajurel B, Marhatta MN, Amatya R. Apnea testing with continuous positive airway pressure for the diagnosis of brain death in a patient with poor baseline oxygenation status. *Indian J Crit Care Med* 2014;18:331-3.

**Source of Support:** Nil, **Conflict of Interest:** None declared.