

Curious association between *Plasmodium vivax* malaria and nontraumatic acute subdural hematoma

Sir,

A 65-year-old male was brought to the emergency department with acute onset of altered consciousness level. Relatives informed that the patient was having high-grade fever 4 days back that lasted for 2 days. On the day of admission, the patient suddenly lost his consciousness following an episode of vomiting. Relatives denied any history of abnormal limb movements or frothing from mouth or any facial deviation. Repeated questioning of all the available relatives was negative for history of head trauma (even trivial). On examination, he was afebrile with heart rate 76/min, regular, blood pressure 130/80 mmHg. He was stuporous, Glasgow coma scale-E1 M5 V1 with bilateral equal size (2 mm) pupils reacting to light. There was a paucity of movement in the right side with right-sided extensor plantar reflex. There was no hepatosplenomegaly. Respiratory, cardiovascular, and skin examinations were unremarkable.

Computed tomography head showed acute subdural hematoma involving left cerebral convexity with 7 mm midline shift [Figures 1 and 2]. Laboratory investigations revealed leukopenia ($3400/\text{mm}^3$) with normal differential count, thrombocytopenia ($25,000/\text{mm}^3$) with normal hemoglobin level. Blood urea nitrogen and serum creatinine level were mildly elevated (41 and 1.6 mg/dl, respectively). Liver function test, electrocardiography, and chest X-ray did not reveal any abnormality. Peripheral blood film (both thick and thin film) showed *Plasmodium vivax* trophozoites. Rapid test for malaria (lactate dehydrogenase based antigen detection test, First sign) was also positive for *P. vivax*. Dengue serology (NS1, IgG, and IgM dengue) was negative. Patient was intubated and placed on mechanical ventilation. He was started on intravenous artesunate and clindamycin as per WHO guideline and was planned for decompressive craniotomy following platelet transfusion. Only the following day, the patient could be taken up for surgery following eight random donor and one single donor platelet transfusion. Left frontotemporoparietal craniotomy, evacuation of the hematoma and cranioplasty was done [Figure 2]. In

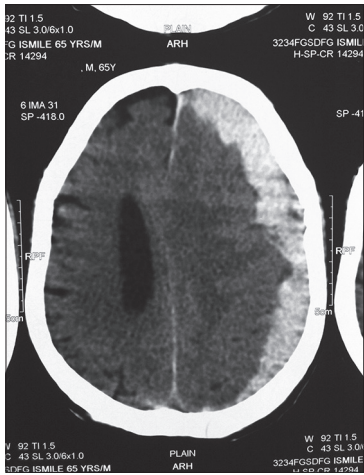

Figure 1: Acute subdural hematoma over left cerebral convexity

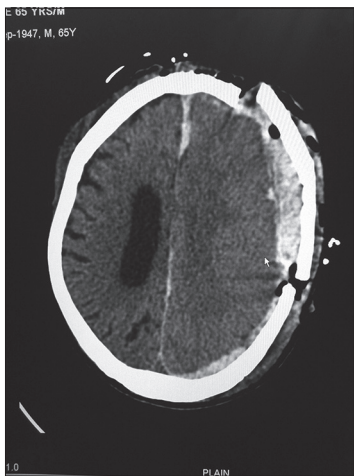


Figure 2: Postcraniotomy

the following days in the intensive care unit patient’s blood film became negative for malaria parasites and platelet count normalized. However, his sensorium never showed improvement-he remained comatose throughout the postoperative course. On day 16 the family decided to take him home against medical advice.

Increasing number of severe manifestations reported in the literature contributed to the increasing interest in *P. vivax* infection recently. In an observational study of 40 cases of severe vivax malaria, Kochar *et al.*, described different complications, including ARDS, acute kidney injury, thrombocytopenia, hepatic dysfunction, and cerebral malaria.^[1] Mixed infection with *Plasmodium falciparum* species was ruled out by PCR method in all these cases.

Falciparum malaria complicated by subdural hematoma has been described in the literature.^[2,3] All these cases had associated thrombocytopenia. To the

best of my knowledge, this is the first case reported in the literature of a case of vivax malaria associated with acute nontraumatic subdural hematoma.

Acknowledgment

I sincerely acknowledge the contribution of my colleagues from the Department of Critical Care Medicine and Department of Neurosurgery, Fortis-Escorts Hospital, Faridabad in managing the patient.

Supradip Ghosh

Department of Critical Care Medicine, Fortis-Escorts Hospital, Faridabad, Haryana, India

Correspondence:

Dr. Supradip Ghosh, Department of Critical Care Medicine, Fortis-Escorts Hospital, Faridabad, Haryana, India. E-mail: intensivist1972@gmail.com

References

1. Kochar DK, Das A, Kochar SK, Saxena V, Sirohi P, Garg S, *et al.* Severe *Plasmodium vivax* malaria: A report on serial cases from Bikaner in northwestern India. *Am J Trop Med Hyg* 2009;80:194-8.
2. Kamali NI, Huda MF, Srivastava VK. Falciparum malaria troubling neurosurgeons. *J Postgrad Med* 2012;58:61-2.
3. Chaudhary SC, Sonkar SK, Kumar V, Gupta A. Falciparum malaria presenting as subdural hematoma. *J Assoc Physicians India* 2011;59:325-6.

Access this article online	
<p>Quick Response Code:</p> 	<p>Website: www.ijccm.org</p>
<p>DOI: 10.4103/0972-5229.132513</p>	