

# The role of inhaled nitric oxide beyond ARDS

Muhammad Faisal Khan, Mohammad Feroz Azfar, Syed Moazzum Khurshid

## Abstract

Patients with traumatic brain injury complicated by acute respiratory distress syndrome (ARDS) are not uncommon in intensive care unit (ICU). The ventilatory management of patients combined with both of these catastrophic conditions is not straightforward. Evidence-based permissive hypercapnia strategy for ARDS could be fatal in patients with intracranial hypertension. Adjunctive use of inhaled nitric oxide (INO) is well-defined as a rescue therapy in severe ARDS, but its specific role in intracranial hypertension is somewhat uncertain. We report a case, which following traumatic brain injury developed both intracranial hypertension and ARDS. INO was given for ARDS, but coincidentally it also improved the raised intracranial pressure (ICP) and patient's neurological outcome. The case report will be followed by literature review on the role of INO in raised ICP.

**Keywords:** Acute respiratory distress syndrome, permissive hypercapnia and INO, raised intracranial pressure, traumatic brain injury

## Access this article online

Website: [www.ijccm.org](http://www.ijccm.org)

DOI: 10.4103/0972-5229.133931

Quick Response Code:



## Introduction

Acute respiratory distress syndrome (ARDS) is not an uncommon feature in patients with traumatic brain injury. The management plan for ARDS requires permissive hypercapnia, whereas, raised intracranial pressure (ICP) is managed by normocapnia or hypocapnia, which in a way are contradictory to each other.<sup>[1]</sup>

The role of inhaled nitric oxide (INO) in ARDS is well-described, while in raised ICP is not yet established. We report a case which showed improvement of raised ICP and ARDS following traumatic brain injury (TBI) with INO.

## Case Report

A 13-year-old boy was brought to the emergency room with multiple injuries following a motor vehicle accident. He was intubated because of low Glasgow Coma Scale (GCS; 5/15). Pupils were equal and reactive,

blood pressure 100/55 mmHg, pulse 110 per min, oxygen saturation 94% on 0.6 FiO<sub>2</sub>, and respiratory rate 16 per min. Trauma X-ray series showed fractures of the left femur and pelvis (stable fracture). Computed tomography (CT) brain showed mild cerebral edema with no midline shift. Patient was transferred to the intensive care unit (ICU) for further management.

Patient was sedated with midazolam 4-6 mg/h and fentanyl 100-150 μ/h. The ventilator (Dräger, Infinity C500, Germany) settings in the ICU were as follows; assist control mode, respiratory rate 14 per min, tidal volume 7 ml/kg (according to ideal body weight), inspiratory flow rate 45 l/min, positive end-expiratory pressure (PEEP) 5 cmH<sub>2</sub>O, and FiO<sub>2</sub> 0.5. Patient's weight and height were 60 kg and 160 cm, respectively (ideal body weight (IBW) 57 kg). Lung mechanics revealed high peak and plateau pressure (35 and 30 cmH<sub>2</sub>O, respectively).

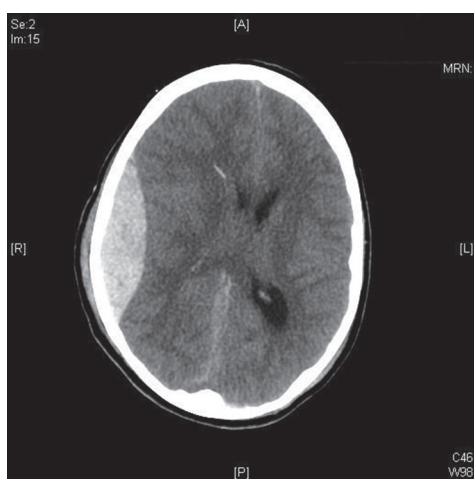
After 24 h, patient's pupil became unequal and CT brain showed right temporoparietal epidural hematoma. Evacuation of hematoma was done, and patient was transferred back to ICU with ICP monitoring device. Initial ICP and cerebral perfusion pressure (CPP) were 17 and 60 mmHg, respectively [Figure 1]. Post-surgery ventilator settings were assist control mode, rate 28, tidal volume 6 ml/kg, FiO<sub>2</sub> 1.0, and PEEP 8 cmH<sub>2</sub>O.

**From:**  
Department of Critical Care, King Khalid University Hospital, King Saud University, Riyadh, Saudi Arabia

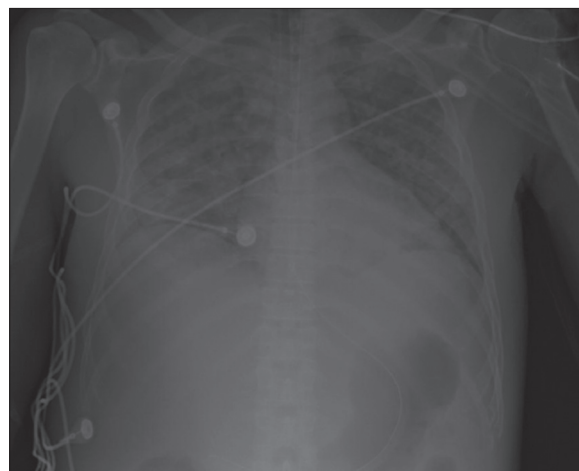
**Correspondence:**  
Dr. Muhammad Faisal Khan  
Department of Critical Care (95), 3<sup>rd</sup> Level Critical Care Building,  
King Khalid University Hospital, P.O. BOX: 2925, Riyadh 11461, Saudi Arabia.  
E-mail: [mfkdr.icu@gmail.com](mailto:mfkdr.icu@gmail.com)

Arterial blood gas showed pH 7.32, PaCO<sub>2</sub> 46, PaO<sub>2</sub> 65, HCO<sub>3</sub> 19 meq/L, and SpO<sub>2</sub> was 93%.

After 48 h, patient developed features of severe ARDS<sup>[2]</sup> [Figure 2]. Tracheal aspirate was negative for any organism. Lung protective ventilation strategy was started as follows; ventilatory rate 32 per min, tidal volume 5-6 ml/kg (300-350 ml), FiO<sub>2</sub> 1.0, and PEEP 16. This ventilatory setting led to increase in ICP from 17 to 28 and reduction of CPP from 60 to 45. Arterial blood gas showed pH 7.24, PaCO<sub>2</sub> 53, and PaO<sub>2</sub> 58. Cisatracurium was used at this stage to paralyze the patient with 0.3 mg/kg/h as maintenance dose after bolus of 0.2 mg/kg. Train of four was also monitored. 20% mannitol (1 g/kg) was used 8-hourly for 24 h with monitoring of serum sodium (target serum sodium: 150-155 mEq/L) and serum osmolality (target osmolality up to 320 mOsm). Norepinephrine was used for 24 h for keeping mean arterial pressure (MAP) above 90 mmHg.



**Figure 1:** Right temporoparietal acute epidural hematoma noted with maximum depth of 2.2 cm and causing mass effect



**Figure 2:** Bilateral lung infiltrate

Patient was started on INO to improve pulmonary mismatching. INO was started after discussion with family members. It was started with 10 ppm, then gradually built up to 35 ppm. Next 12-24 h, PaO<sub>2</sub> and PaCO<sub>2</sub> improved. ICP also showed gradual improvement from 18 to 5. Blood gases were as follows: pH 7.37, PaCO<sub>2</sub> 40, and PaO<sub>2</sub> 128. PEEP reduced from 16 to 10 and FiO<sub>2</sub> from 1.0 to 0.6 [Table 1 and Figure 3].

INO was discontinued after 1 week, and patient was weaned off from the ventilator. Post-extubation patient remained conscious with no neurological deficit. Repeat CT head was normal. Further stay in ICU remained uneventful, and then patient was transferred to the ward. Patient remained in hospital for 2 months as he developed an hospital-acquired infection and then shifted home.

### Discussion

ARDS following TBI is not an uncommon complication. It can lead to hypoxemia and decreased oxygen supply to the brain that can further worsen brain injury.

The management for raised ICP requires PaO<sub>2</sub> around 100, PaCO<sub>2</sub> between 30 and 35, and CPP 50-70 mmHg.<sup>[3]</sup> On contrary, “permissive hypercapnia” may be required for patients with severe ARDS.<sup>[4]</sup>

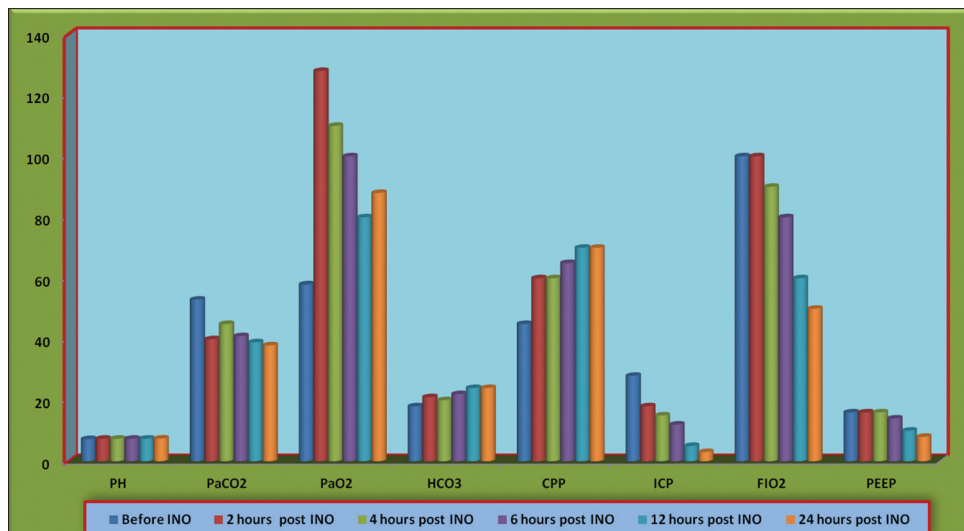
INO is increasingly used in ICUs for patient with ARDS, but its use in traumatic brain injury patients is not yet clear. There are two case reports (one in adult and other in a child);<sup>[5,6]</sup> so far, highlighting the successful use of INO in patient with severe traumatic brain injury complicated with ARDS.

The role of INO is still experimental in traumatic brain injury. It is a known fact that ischemia is one of the leading causes of secondary brain damage, and

**Table 1: Change in ABGs, ICP, CPP, FiO<sub>2</sub>, and PEEP before and after INO**

Variables	INO					
	Before	2 hours post	4 hours post	6 hours post	12 hours post	24 hours post
PH	7.24	7.37	7.35	7.37	7.39	7.42
PaCO <sub>2</sub> (mmHg)	53	40	45	41	39	38
PaO <sub>2</sub> (mmHg)	58	128	110	100	80	88
HCO <sub>3</sub> (mEq/L)	18	21	20	22	24	24
CPP (mmHg)	45	60	60	65	70	70
ICP (mmHg)	28	18	15	12	5	3
FiO <sub>2</sub>	100	100	90	80	60	50
PEEP (cmH <sub>2</sub> O)	16	16	16	14	10	8

ABG: Arterial blood gas; ICP: Intracranial pressure; CPP: Cerebral perfusion pressure; PEEP: Positive end-expiratory pressure; INO: Inhaled nitric oxide



**Figure 3:** Change in ABGs, ICP, CPP, FiO<sub>2</sub>, and PEEP before and after the use of INO. ABG = Arterial blood gas, ICP = intracranial pressure, CPP = cerebral perfusion pressure, PEEP = positive end-expiratory pressure, INO = inhaled nitric oxide

worsening of cerebral blood flow (CBF) is a dominating feature in the progression of pericontusional ischemic changes.<sup>[7]</sup> The role of a selective vasodilator with action on hypoxic/ischemic tissue would certainly be a viable strategy for the treatment of pericontusional ischemia; however, such a therapeutic option is not yet available. Terpolilli *et al.*,<sup>[8,9]</sup> observed the protective effect of INO as it selectively dilates cerebral resistant vessels in hypoperfused areas, and thus, improved collateral blood circulation in the brain. It was hypothesized by Papadimos<sup>[10]</sup> that INO could improve metabolic function and prevent death of the ischemic penumbra under conditions of transient reduction of CBF. Furthermore, regional vascular protective effects were nicely described by Cannon *et al.*<sup>[11]</sup> As a selective cerebral vasodilator, it may cause inverse steal or Robin Hood effect<sup>[12]</sup> in brain injured tissue that can play as a neuroprotective role.

Vavilala *et al.*,<sup>[6]</sup> first, described the safe use of INO in TBI. Papadimos *et al.*,<sup>[5]</sup> successfully used INO to decrease ICP in a patient with severe TBI complicated by ARDS. This study further elucidated the anti-inflammatory and neuroprotective effect of INO in traumatic brain injury.

In our case report, the clinical scenario for using INO was not very much different from the case presented by Papadimos *et al.*,<sup>[5]</sup> but interestingly in our case the timing of initiation of INO was early with encouraging cerebral outcome. The use of INO showed concomitant reduction of arterial PaCO<sub>2</sub> and ICP, which lead to improvement in CPP. This improvement in ICP and CPP can be hypothetically correlated to improvement in PaCO<sub>2</sub> and PaO<sub>2</sub>, but the cerebral protective effect of

INO is not new in the literature, though it is still limited to animal studies and case reports. This case report not only emphasized the early use of INO in TBI complicated with severe ARDS and raised ICP, but it also opens the discussion to use INO as one of the cerebral protective measures in future.

In conclusion, INO in principle can be considered for improvement of cerebral perfusion in patient with raised ICP particularly following TBI. More clinical studies, particularly randomized clinical trials (RCTs) are needed to validate it further.

### References

- Haddad SH, Arabi YM. Critical care management of severe traumatic brain injury in adults. *Scand J Trauma Resusc Emerg Med* 2012;20:12.
- ARDS Definition Task Force, Ranieri VM, Rubenfeld GD, Thompson BT, Ferguson ND, Caldwell E, Fan E, *et al.* Acute respiratory distress syndrome: The Berlin Definition. *JAMA* 2012;307:2526-33.
- Protheroe RT, Gwinnutt CL. Early hospital care of severe traumatic brain injury. *Anaesthesia* 2011;66:1035-47.
- O’Croinin D, Ni Chonghaile M, Higgins B, Laffey JG. Bench-to bedside review: Permissive hypercapnia. *Crit Care* 2005;9:51-9.
- Papadimos TJ, Medhkour A, Yermal S. Successful use of inhaled nitric oxide to decrease intracranial pressure in a patient with severe traumatic brain injury complicated by acute respiratory distress syndrome: A role for an anti-inflammatory mechanism? *Scand J Trauma Resusc Emerg Med* 2009;17:5.
- Vavilala MS, Roberts JS, Moore AE, Newell DW, Lam AM. The influence of inhaled nitric oxide on cerebral blood flow and metabolism in a child with traumatic brain injury. *Anesth Analg* 2001;93:351-3.
- Charriat-Marlangue C, Bonnin P, Gharib A, Leger PL, Villapol S, Poceard M, *et al.* Inhaled nitric oxide reduces brain damage by collateral recruitment in a neonatal stroke model. *Stroke* 2012;43:3078-84.
- Terpolilli NA, Kim SW, Thal SC, Kataoka H, Zeisig V, Nitzsche B, *et al.* Inhalation of nitric oxide prevents ischemic brain damage in experimental stroke by selective dilatation of collateral arterioles. *Circ Res* 2012;110:727-38.
- Terpolilli NA, Kim SW, Thal SC, Kuebler WM, Plesnila N. Inhaled nitric

- oxide reduces secondary brain damage after traumatic brain injury in mice. *J Cereb Blood Flow Metab* 2013;33:311-8.
10. Papadimos TJ. The beneficial effects of inhaled nitric oxide in patients with severe traumatic brain injury complicated by acute respiratory distress syndrome: A hypothesis. *J Trauma Manag Outcomes* 2008;2:1.
  11. Cannon RO 3<sup>rd</sup>, Schechter AN, Panza JA, Ognibene FP, Pease-Fye ME, Waclawiw MA, *et al.* Effects of inhaled nitric oxide on regional blood flow are consistent with intravascular nitric oxide delivery. *J Clin Invest* 2001;108:279-87.
  12. El Kebir D, Taha R, Hubert B, Gauvin D, Gangal M, Blaise G. The anti-inflammatory effect of inhaled nitric oxide on pulmonary inflammation in a swine model. *Can J Physiol Pharmacol* 2005;83:252-8.

**How to cite this article:** Khan MF, Azfar MF, Khurshid SM. The role of inhaled nitric oxide beyond ARDS. *Indian J Crit Care Med* 2014;18:392-5.

**Source of Support:** Nil, **Conflict of Interest:** None declared.

### Author Help: Online submission of the manuscripts

Articles can be submitted online from <http://www.journalonweb.com>. For online submission, the articles should be prepared in two files (first page file and article file). Images should be submitted separately.

- 1) **First Page File:**  
Prepare the title page, covering letter, acknowledgement etc. using a word processor program. All information related to your identity should be included here. Use text/rtf/doc/pdf files. Do not zip the files.
- 2) **Article File:**  
The main text of the article, beginning with the Abstract to References (including tables) should be in this file. Do not include any information (such as acknowledgement, your names in page headers etc.) in this file. Use text/rtf/doc/pdf files. Do not zip the files. Limit the file size to 1 MB. Do not incorporate images in the file. If file size is large, graphs can be submitted separately as images, without their being incorporated in the article file. This will reduce the size of the file.
- 3) **Images:**  
Submit good quality color images. Each image should be less than 4096 kb (4 MB) in size. The size of the image can be reduced by decreasing the actual height and width of the images (keep up to about 6 inches and up to about 1800 x 1200 pixels). JPEG is the most suitable file format. The image quality should be good enough to judge the scientific value of the image. For the purpose of printing, always retain a good quality, high resolution image. This high resolution image should be sent to the editorial office at the time of sending a revised article.
- 4) **Legends:**  
Legends for the figures/images should be included at the end of the article file.