

Amlodipine poisoning revisited: Acidosis, acute kidney injury and acute respiratory distress syndrome

Kushal Naha, J. Suryanarayana, Riffat Abdul Aziz, Barkur Ananthakrishna Shastry

Abstract

We report the case of an 18-year-old girl presenting with shock following ingestion of 85 mg of amlodipine and 850 mg of atenolol with suicidal intent. Subsequently, the patient developed severe metabolic acidosis, acute kidney injury, and acute respiratory distress syndrome, which were managed conservatively. The patient ultimately made a full recovery. Given the popularity of amlodipine and atenolol as antihypertensive drugs in this part of the world, it is likely that more such cases will be encountered in the future. Physicians should be aware of the severe complications that can develop with amlodipine overdose.

Keywords: Acidosis, acute respiratory distress syndrome, amlodipine, poisoning

Access this article online

Website: www.ijccm.org

DOI: 10.4103/0972-5229.136078

Quick Response Code:



Introduction

Calcium channel blockers (CCB) constitute the leading form of cardiovascular drug overdose and have been implicated in up to 48% of deaths resulting from such overdose.^[1] Treating patients with overdose of CCBs can challenge even experienced physicians. The difficulty arises because patients severely poisoned with CCBs can develop profound refractory bradycardia, hypotension and either cardiogenic or noncardiogenic pulmonary edema. This case was reported to raise awareness about the severe complications of amlodipine poisoning, as well as the appropriate therapeutic approach to these complications among practicing medical professionals.

Case Report

The case we present here is about an 18-year-old girl who was referred to our hospital from a local health center with shock, following the consumption of 17 tablets containing a fixed dose combination of amlodipine 5 mg and atenolol 50 mg. Gastric lavage had been performed at the local center prior to referral, approximately 2 h

after the consumption of the tablets. She developed hypotension 2 h later and was transferred to our hospital 7 h after the time of ingestion. On questioning, she admitted to having ingested the tablets with suicidal intent. She denied concomitant consumption of alcohol or any other drugs.

At presentation, she was confirmed to be hypotensive, with cold peripheries, a thready pulse at 130/min and a blood pressure of 70/50 mm Hg in the supine position. Respiratory rate was 26/min. The patient was conscious and appeared anxious. Her Glasgow Coma scale was 15/15. Systemic examination including cardiac and respiratory systems was entirely normal. Hourly urine output was initially below 0.5 ml/kg body weight but improved rapidly after infusion of intravenous (IV) fluids and vasopressors.

Pulse oximetry showed mild hypoxia (spO₂: 88% on room air), which improved with oxygen supplementation. Routine laboratory tests showed mild renal failure (serum urea: 49 mg/dl, creatinine: 1.9 mg/dl). Other tests including complete blood counts, liver function tests and serum electrolytes were within the normal limits. Arterial blood gas analysis showed relative hypoxia with severe metabolic acidosis and respiratory compensation (pH: 7.31, pO₂: 86 mm Hg, pCO₂: 12 mm Hg, HCO₃: 8.8 mmol/l, FiO₂: 0.6). Calculated parameters showed high anion gap

From:

Department of Medicine, Kasturba Hospital, Manipal, Karnataka, India

Correspondence:

Dr. Kushal Naha, Department of Medicine, Kasturba Hospital, Manipal - 576 104, Karnataka, India.
E-mail: kushalnaha@gmail.com

metabolic acidosis (anion gap: 22), a $\text{PaO}_2/\text{FiO}_2$ ratio of 143 and an elevated A-a gradient (327 mm Hg). Serum lactate level was normal (9.7 mg/dl). Electrocardiography demonstrated sinus tachycardia with normal P-R and Q-T intervals. Chest X-ray performed immediately after admission was normal.

The patient was immediately administered a 1 L bolus of IV normal saline. When hypotension failed to improve, inotropic support was initiated with an IV infusion of norepinephrine.

As hypoxia continued to worsen over the next 24 h, chest X-ray was repeated and revealed bilateral extensive inhomogeneous shadows involving the middle and lower zones of both lung fields; both upper zones were spared [Figure 1]. Transthoracic echocardiography was performed, and cardiac dysfunction was excluded (ejection fraction 58%, no evidence of diastolic dysfunction). Although direct measurement of pulmonary venous pressure could not be done, the overall picture was strongly suggestive of acute respiratory distress syndrome (ARDS).

Oxygen supplementation was provided initially through a venturi mask, and thereafter by means of non-invasive ventilation. IV calcium gluconate (30 mL of 10% calcium gluconate IV stat followed by an infusion of 10% calcium gluconate at 10 mL/h) was administered when the patient developed ARDS.

The patient responded to inotropic support with progressive resolution of hypotension over the next 48 h. ARDS also improved over the same period of time. Eight days after the episode, she had recovered completely

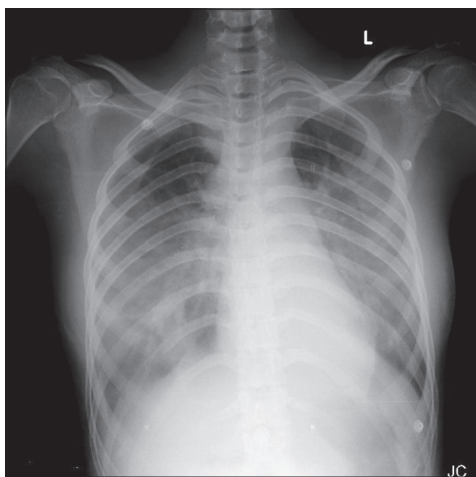


Figure 1: Chest X-ray showing bilateral extensive inhomogeneous shadows involving the middle and lower zones of both lung fields, with sparing of both upper zones

from hypotension, hypoxia and acute kidney injury. She was subsequently discharged after psychiatric evaluation and counseling.

Discussion

There are a limited number of case reports describing severe amlodipine intoxication; understandably therefore, there are no standardized guidelines for managing such cases. Gastrointestinal decontamination with activated charcoal constitutes the first line of therapy for patients with CCB overdose;^[2] unfortunately this approach is only beneficial when used within the 1st h of consumption, and could not be employed in our case. Other therapeutic strategies that have been used with varying degrees of success include the hyperinsulinemia-euglycemia technique,^[3] continuous IV infusion of calcium,^[4] and inotropic support with dopamine, norepinephrine, dobutamine and levosimendan.^[5] In this case, it was decided to administer calcium infusion when the patient developed ARDS. This approach contrasts sharply with most case reports, wherein calcium infusion was employed to correct hemodynamic instability. For instance, Saravu and Balasubramanian described a young male with late onset ARDS after consuming 400 mg of amlodipine, who received calcium gluconate for hypotension, prior to the onset of ARDS.^[6] Rizvi *et al.* described a female with refractory hypotension following consumption of 280 mg of amlodipine, in whom treatment with calcium gluconate infusion yielded only marginal improvement in hypotension.^[7] Similarly Hasson *et al.* have reported another young female with refractory hypotension and ARDS after consuming 280 mg of amlodipine.^[8] Again, the patient was initiated on IV calcium gluconate primarily for the management of hypotension. Yet another case series by Ghosh and Sircar describes two individuals with refractory hypotension following amlodipine intoxication who had a successful outcome incorporating IV calcium infusion in their management.^[4] Kute *et al.* also described a patient with ARDS and hypotension who was administered IV calcium only when hypotension failed to respond to conventional inotropes.^[9] Selective pre-capillary vasodilation producing excessive pulmonary capillary transudation has been suggested as a mechanism for development of ARDS in patients with CCB overdose.^[10] In such a situation, administration of IV calcium raises extracellular calcium concentration, driving calcium intracellularly and thus reversing CCB induced vasodilation. Intuitively, such pharmacological antagonism would suggest that calcium gluconate be useful for primary management of CCB induced pulmonary edema. This hypothesis is consistent with the temporal patterns seen in this case, wherein progression of ARDS was seen in the first 24 h after

admission despite correction of hypotension. However, further studies are required to confirm this hypothesis.

Another notable finding in this case was the development of severe metabolic acidosis, in the absence of lactic acidosis. This feature is also noticeable in most of the cases described above. We suggest that severe metabolic acidosis might be an independent sequel of amlodipine intoxication, with contribution from systemic hypotension and acute kidney injury.

Interestingly, this patient did not develop any overt signs of beta-blocker toxicity such as conduction blocks or even bradycardia despite the ingestion of 850 mg of atenolol, instead presenting with reflex tachycardia probably secondary to amlodipine induced vasodilation and hypotension. It is possible that the relatively poor bioavailability of oral atenolol^[11] along with proven variability of biological response to high doses of atenolol could be responsible for the absence of beta-blocker toxicity in this instance. Pertinently, doses of up to 1200 mg/day of atenolol have been reported to be well-tolerated without clinical manifestations.^[12]

The relatively innocuous adverse effects of amlodipine such as peripheral edema and constipation, have resulted in a general perception that amlodipine is a safe and well-tolerated drug. While, this is certainly true of amlodipine in therapeutic doses, physicians should be aware of the severe organ dysfunction that can arise from overdosage of amlodipine given the popularity of this drug as an antihypertensive.

References

1. DeWitt CR, Waksman JC. Pharmacology, pathophysiology and management of calcium channel blocker and beta-blocker toxicity. *Toxicol Rev* 2004;23:223-38.
2. Patel NP, Pugh ME, Goldberg S, Eiger G. Hyperinsulinemic euglycemia therapy for verapamil poisoning: A review. *Am J Crit Care* 2007;16:498-503.
3. Azendour H, Belyamani L, Atmani M, Balkhi H, Haimour C. Severe amlodipine intoxication treated by hyperinsulinemia euglycemia therapy. *J Emerg Med* 2010;38:33-5.
4. Ghosh S, Sircar M. Calcium channel blocker overdose: Experience with amlodipine. *Indian J Crit Care Med* 2008;12:190-3.
5. Varpula T, Rapola J, Sallisalmi M, Kurola J. Treatment of serious calcium channel blocker overdose with levosimendan, a calcium sensitizer. *Anesth Analg* 2009;108:790-2.
6. Saravu K, Balasubramanian R. Near-fatal amlodipine poisoning. *J Assoc Physicians India* 2004;52:156-7.
7. Rizvi I, Ahmad A, Gupta A, Zaman S. Life-threatening calcium channel blocker overdose and its management. *BMJ Case Rep* 2012;2012:1-4.
8. Hasson R, Muleahy V, Tahir H. Amlodipine poisoning complicated with acute non-cardiogenic pulmonary oedema. *BMJ Case Rep* 2011;2011:1-3.
9. Kute VB, Shah PR, Goplani KR, Gumber MR, Vanikar AV, Trivedi HL. Successful treatment of refractory hypotension, noncardiogenic pulmonary edema and acute kidney injury after an overdose of amlodipine. *Indian J Crit Care Med* 2011;15:182-4.
10. Humbert VH Jr, Munn NJ, Hawkins RF. Noncardiogenic pulmonary edema complicating massive diltiazem overdose. *Chest* 1991;99:258-9.
11. Keerthi H, Panakanti PK, Yamsani MR. Design and characterization of atenolol transdermal therapeutic systems: Enhancement of permeability via iontophoresis. *PDA J Pharm Sci Technol* 2012;66:318-32.
12. O'grady J, Anderson S, Pringle D. Successful treatment of severe atenolol overdose with calcium chloride. *CJEM* 2001;3:224-7.

How to cite this article: Naha K, Suryanarayana J, Aziz RA, Shastry BA. Amlodipine poisoning revisited: Acidosis, acute kidney injury and acute respiratory distress syndrome. *Indian J Crit Care Med* 2014;18:467-9.

Source of Support: Nil, **Conflict of Interest:** None declared.