

Scrub typhus presenting as Purpura fulminans

Suhasini Tirumala, Bijayini Behera¹, Srikanth Jawalkar², Pradeep Kumar Mishra³, Pavithra Vani Patalay⁴, Sudha Ayyagari⁵, Pavani Nimmala¹

Abstract

Seriously ill patients presenting with purpura fulminans, sepsis and multi-organ failure often require extensive diagnostic workup for proper diagnosis and management. Host of common infections prevalent in the tropics, e.g. malaria, dengue; other septicemic infections e.g. meningococemia, typhoid, leptospirosis, toxic shock syndrome, scarlet fever, viral exanthems like measles, infectious mononucleosis, collagen vascular diseases (Kawasaki disease, other vasculitis) diseases, and adverse drug reactions are often kept in mind, and the index of suspicion for rickettsial illness is quite low. We present a case of Indian tick typhus presenting with purpura fulminans (retiform purpura all over the body), sepsis and multiorgan failure without lymphadenopathy and eschar, successfully treated with doxycycline and discharged home. Hence, a high index clinical suspicion and prompt administration of a simple therapy has led to successful recovery of the patient.

Keywords: Indian tick typhus, purpura, *Rickettsia*, Weil–Felix test, doxycycline

Access this article online

Website: www.ijccm.org

DOI: 10.4103/0972-5229.136081

Quick Response Code:



Introduction

Rickettsial fevers, particularly scrub typhus are some of the important reemerging diseases of present days.^[1] Indian tick typhus (ITT), caused by *Rickettsia conorii* subsp. *indica* is a disease of the spotted fever bio-group of *Rickettsia*, spread by the bite of an infected tick.^[2] ITT is not the common variant of typhus fever in India.^[3] There had been a few reports of ITT from Pune district of Maharashtra, Himachal Pradesh, in a French traveller returning from India and in Haryana.^[4-7] ITT clinically differs from other spotted fever group (SFG) in that maculopapular rash often turns purpuric, absence of inoculation eschar (eschar if present, is always single), and absence of lymphadenopathy.^[8] Recently, there are few published reports of occurrence

of gangrene of the extremities in case of ITT, which is an uncommon complication in cases of spotted fever rickettsiosis.^[9,10] Along with gangrene, these cases had severe manifestations of sepsis and multiorgan dysfunction syndrome such as acute kidney injury, liver dysfunction, delirium, and seizure.^[10] Hereby, we present a life-threatening case of ITT presenting with atypical skin manifestations in the form of purpura fulminans (retiform purpura all over the body), bullous eruptions and multiorgan failure. The Weil–Felix (W-F) test was very helpful in confirming the diagnosis.

Case Report

A 45-year-old male patient from Nanded, Maharashtra, was admitted to our intensive care unit (ICU) with fever of 1 week, cough, generalized weakness, loose motions, and altered sensorium of 2 days duration with a presumptive diagnosis of viral encephalitis as he had a brief history of herpetiform rash on the back prior to fever. The rash had become more generalized with a few petechiae and one ecchymotic patch. On examination, he was disoriented, irritable, not obeying verbal commands, but moving all limbs. He had no lymphadenopathy and no eschar could be identified. He had no other comorbidities apart from chronic alcoholism and heavy

From:

Departments of Critical Care Medicine, ¹Microbiology, ²Neurology, ³General Medicine, ⁴Dermatology, ⁵Pathology, ⁶Yashoda Hospital, Secunderabad, Andhra Pradesh, India

Correspondence:

Dr. Bijayini Behera, Yashoda Hospital, Secunderabad, Andhra Pradesh, India.
E-mail: drbinny2004@gmail.com

The 1st Author's Present Affiliation: Professor, HOD, Critical Care, NRI Medical College and Hospital, Guntur Dist. Andhra Pradesh, India

The 2nd Author is Presently Affiliation: Assistant Professor, Department of Microbiology, All India Institute of Medical Sciences, Bhubaneswar

smoking. Routine laboratory investigations revealed severe thrombocytopenia (30,000/cumm), raised urea (89 mg/dl) and creatinine (3 mg/dl), raised liver enzymes with increased serum bilirubin (total bilirubin 9.1 mg/dl, direct 6.7 mg/dl, increased lactate and ammonia, normal coagulation parameters, including fibrinogen. In view of oropharyngeal bleeding and severe thrombocytopenia, platelets were transfused. Arterial blood gas analysis revealed severe metabolic acidosis, which improved with fluid resuscitation and the urine output improved. Patient was started on broad spectrum antibiotics [I.V meropenem and ciprofloxacin] in view of sepsis and multiorgan dysfunction. He was intubated and connected to mechanical ventilator support as he developed neurologic, hemodynamic and respiratory deterioration. A magnetic resonance imaging brain was normal. A generalized retiform purpuric rash (purpura fulminans) was noted all over the body along with high grade fever and hypotension [Figure 1]. Blood was negative for malaria parasite; dengue and *Leptospira* serology were negative (dengue immunoglobulin M [IgM] capture enzyme-linked immunosorbent assay [ELISA], Panbio Pty., Ltd., Brisbane, Australia. *Leptospira* IgM ELISA, Panbio Pty., Ltd., Brisbane, Australia). A presumptive diagnosis of meningococemia was made, while awaiting blood culture report. Gram stains of the skin biopsy failed to reveal intracellular/extracellular Gram-negative diplococci and serum/urine *Neisseria meningitidis* Ag detection were negative (BD Directigen Meningitis Combo Test, Becton Dickinson, USA). Lumbar puncture was not performed due to low platelet count. Venereal disease research laboratory, CARBOGEN, rapid plasma reagin card test (Tulip Diagnostics Pvt., Ltd., India), acute hepatitis profile (IgM hepatitis A virus, IgM hepatitis E virus, hepatitis B surface antigen, IgM antihepatitis B core), hepatitis C virus antibodies were negative (by chemiluminescent immunoassays [Abbott Architect, (Abbott Laboratories, Abbott Park, IL, USA)]) vasculitis workup (antinuclear antibody profile, perinuclear antineutrophil cytoplasmic antibody, cytoplasmic antineutrophil cytoplasmic antibody, cryoglobulin, compliment C3 and C4) didn't reveal any abnormality (Euroimmun, Lübeck, Germany). A set of three blood cultures was drawn before starting antimicrobials and urine culture were sterile. W-F test revealed significant titer (OX-2 [1:320], OX-19 [1:40] OX-K [1:40] [PROGEN, Tulip Diagnostics, Goa, India] serology to *Orientia tsutsugamushi* [scrub typhus] was negative [SD tsutsugamushi, Bioline®]) The patient was immediately started on doxycycline. There was no increase in titers when the test was repeated after 1 week. Patient subsequently developed bullous eruptions on the purpuric lesions [Figure 2]. Skin biopsy revealed mildly hyperkeratotic and flattened epidermis, widespread

separation of the epidermis, and dermis [Figure 3]. Direct immunofluorescence study was negative for immunoglobulin A, immunoglobulin G, IgM and C3C in the epidermis and dermis. Toxic epidermal necrosis, fixed drug eruption (drug hypersensitivity) and graft versus host disease were less likely due to the presence of prominent vasculitis.

As the patient improved neurologically and hemodynamically, after 48 h of doxycycline therapy, he was extubated and shifted out of ICU. The serum creatinine improved from 3 to 1 mg/dl, though the liver enzymes were still elevated, serum bilirubin decreased from 9.1 to 2.5 mg/dl. The retiform rash started to fade and patient improved, clinically [Figure 4]. He was discharged after total 2 weeks of hospital stay.

Discussion

Indian tick typhus, caused by *R. conorii* subsp. *indica* is a disease of the spotted fever biogroup of *Rickettsia*, spread by the bite of an infected tick.^[1,2] The disease is characterized by sudden onset of moderate to high grade fever, malaise, deep muscle pain, headache, and conjunctival suffusion.^[8] Rash is usually maculopapular to start with, begins on the 3rd day of fever in the extremities, moves centripetally and involves rest of the body.^[8] ITT also differs from mediterranean spotted fever, the disease caused by the type strain of *R. conorii*, in that the rash is often purpuric and an inoculation eschar at the bite site is seldom identified.^[8] Between 1996 and 1998, serological testing amongst residents of South India, who presented with pyrexia of unknown origin confirmed that spotted fever rickettsiosis continues to occur in south India.^[11] All the documented cases so far have been diagnosed by the geographic prevalence of rickettsial species, clinical features, nonspecific serologic tools, such as the W-F test and response to treatment. The only documented case of infection diagnosed by strain specific serologic testing was published by Parola *et al.*, in a French traveler returning from India.^[6]

Weil-Felix test, based on detection of antibodies to various proteus antigens with cross reacting epitopes to antigens of genus rickettsiae (except *Rickettsia akari*) has low sensitivity and specificity for diagnosis of these infections, has been evaluated to be useful in developing countries as first diagnostic step in diagnosis of rickettsial diseases.^[12] Either a four-fold rise in agglutinin titer in paired sera or single titer of more than equal to 1:320 is considered diagnostic for infection with these febrile agents.^[12] Whole cells of *Proteus vulgaris* OX-2 react strongly with sera from persons infected with SFG

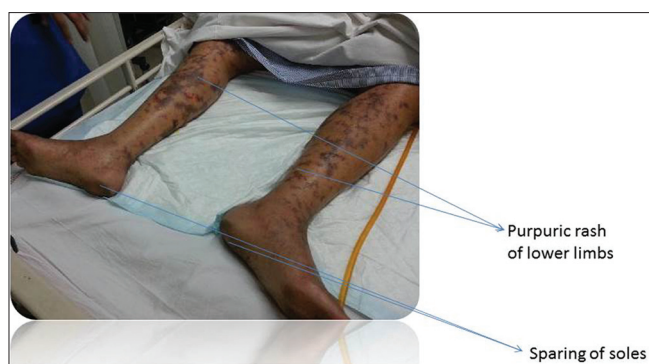

Figure 1: Purpuric rash in the lower limbs; note soles are not involved

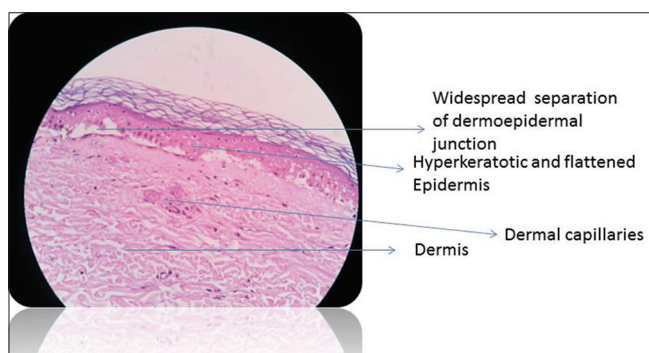


Figure 3: Mildly hyperkeratotic and flattened epidermis, widespread separation of the epidermis and dermis

rickettsiae except Rocky Mountain spotted fever (RMSF) and whole cells of *P. vulgaris* OX-19 react with sera from persons infected with typhus group rickettsiae as well as with RMSF.^[12] One of the major limitations of W-F test is the cross-reactivity among several rickettsial species.^[12] Specific investigations like immunofluorescence, Western blot or polymerase chain reaction based tests, which are helpful in making an accurate diagnosis of rickettsial diseases are expensive and not readily available.^[12]

Our patient, a villager, had no occupational history but belonged to Maharashtra, where tick borne rickettsiosis is prevalent. He had pneumonitis, thrombocytopenia and deranged liver function tests, which is not typical of ITT. The reticulate ecchymotic patches sparing palms, sole along with hypotension, shock, requiring inotropic support, altered level of consciousness led to an initial suspicion of meningococemia. Subsequently, bullous eruptions appeared on the hemorrhagic rash which is not the usual presentation of ITT. The W-F test (OX-2 titer, 1;320) was very helpful in coming to a diagnosis. He was successfully treated with doxycycline. Broad spectrum antibiotics were stopped after results of weil-felix tests were obtained. Considerable clinical improvements were noted within 48 hours of Doxycycline. He was given total 14 days of doxycycline treatment.

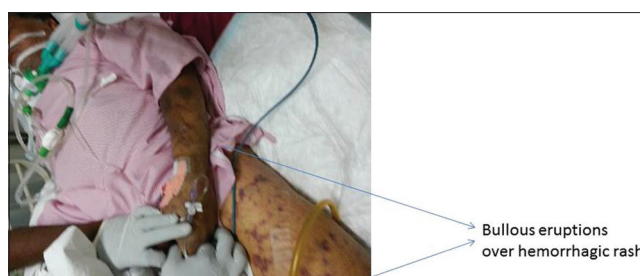


Figure 2: Bullous eruptions over the hemorrhagic rash

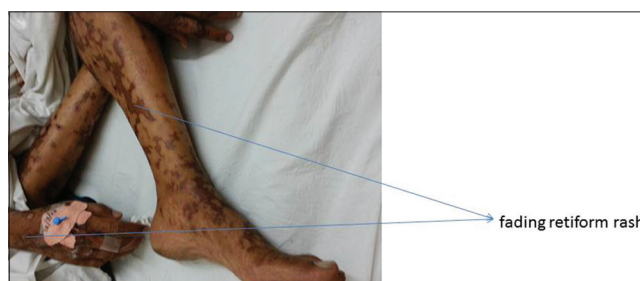


Figure 4: Healing hemorrhagic rash at the time of discharge

References

1. Chaudhry D, Goyal S. Scrub typhus-resurgence of a forgotten killer. *Indian J Anaesth* 2013;57:135-6.
2. Sentausa E, El Karkouri K, Robert C, Raoult D, Fournier PE. Genome sequence of *Rickettsia conorii* subsp. indica, the agent of Indian tick typhus. *J Bacteriol* 2012;194:3288-9.
3. Rath N, Rath A. Rickettsial infections: Indian perspective. *Indian Pediatr* 2010;47:157-64.
4. Padbidri VS, Rodrigues JJ, Shetty PS, Joshi MV, Rao BL, Shukla RN. Tick-borne rickettsioses in Pune district, Maharashtra, India. *Int J Zoonoses* 1984;11:45-52.
5. Mahajan SK, Kashyap R, Sankhyani N, Sharma V, Rolain JM, Prasher BS, et al. Spotted fever group rickettsioses in Himachal Pradesh. *J Assoc Physicians India* 2007;55:868-70.
6. Parola P, Fenollar F, Badiaga S, Brouqui P, Raoult D. First documentation of *Rickettsia conorii* infection (strain Indian tick typhus) in a Traveler. *Emerg Infect Dis* 2001;7:909-10.
7. Chaudhry D, Garg A, Singh I, Tandon C, Saini R. Rickettsial diseases in Haryana: Not an uncommon entity. *J Assoc Physicians India* 2009;57:334-7.
8. Jayaseelan E, Rajendran SC, Shariff S, Fishbein D, Keystone JS. Cutaneous eruptions in Indian tick typhus. *Int J Dermatol* 1991;30:790-4.
9. Kumar M, Singh R, Yadav M. Indian tick typhus presenting with gangrene: A case report from an urban slum of Delhi. *Indian J Pediatr* 2014;81:95-7.
10. Joshi HS, Thomas M, Warriar A, Kumar S. Gangrene in cases of spotted fever: A report of three cases. *BMJ Case Reports* 2012; doi:10.1136/ber-2012-007295.
11. Mathai E, Lloyd G, Cherian T, Abraham OC, Cherian AM. Serological evidence for the continued presence of human rickettsioses in Southern India. *Ann Trop Med Parasitol* 2001;95:395-8.
12. Mittal V, Gupta N, Bhattacharya D, Kumar K, Iehlpujani RL, Singh S, et al. Serological evidence of rickettsial infections in Delhi. *Indian J Med Res* 2012;135:538-41.

How to cite this article: Tirumala S, Behera B, Jawalkar S, Mishra PK, Patalay PV, Ayyagari S, Nimmala P. Scrub typhus presenting as Purpura fulminans. *Indian J Crit Care Med* 2014;18:476-8.

Source of Support: Nil, **Conflict of Interest:** None declared.