

# Perioperative management of two cases of hemophilia with spontaneous intracerebral hemorrhage undergoing emergency craniotomy in resource constrained setup of Nepal

G. S. Shrestha<sup>1,2</sup>, B. Poudyal<sup>3</sup>, A. S. Bhattarai<sup>1</sup>, P. S. Shrestha<sup>1</sup>, G. Sedain<sup>4</sup>, N. Acharya<sup>3</sup>

## Abstract

Patients with hemophilia are prone to develop spontaneous intracranial hemorrhage. It carries a significant risk of morbidity and mortality. In this case series, we report two cases of hemophilia who suffered spontaneous intracerebral hemorrhage with features of raised intracranial pressure and were successfully managed perioperatively. The patients were managed with early intensive care unit management, measures to reduce intracranial pressure, perioperative clotting factor administration, airway management and surgery to decrease the raised intracranial pressure. Both patients improved following surgery and were discharged home. Perioperative multidisciplinary management of hemophilia is discussed in this series.

**Keywords:** craniotomy, hemophilia, intracerebral hemorrhage, perioperative care

## Access this article online

**Website:** [www.ijccm.org](http://www.ijccm.org)

**DOI:** 10.4103/0972-5229.144023

**Quick Response Code:**



## Introduction

Hemophilia is an X-linked recessive hemorrhagic disease due to mutations in the *F8* gene or *F9* gene. It affects one in 10,000 males, with hemophilia A representing 80% of all cases.<sup>[1]</sup> In patients with Hemophilia, intracranial hemorrhage (ICH) is an important cause of morbidity and mortality with the overall incidence of 2.2-7.5%.<sup>[2]</sup> Clotting Factor Concentrate replacement, neurosurgery and aggressive airway management is essential for comatose patients.<sup>[3]</sup> A multidisciplinary approach involving hematologist, neuro-intensivist, neurosurgeon, neurophysician and neuro-anesthesiologist is crucial for a successful outcome. To the best of our knowledge, there are a very few reports about ICH in severe hemophilia in

developing countries.<sup>[2]</sup> We are reporting the case series of this kind for the first time in Nepal.

## Case Reports

### Case 1

A 19-year-old male weighing around 50 kg, a diagnosed case of hemophilia A, presented with sudden onset of loss of consciousness. Patient had Glasgow coma scale (GCS) score of 8 (E2 V1 M5) with unequal pupils. Computed tomography (CT) scan revealed left intracerebral hematoma with mass effect and midline shift of 1.23 cm. Activated Partial Thromboplastin Time (APTT) was 82 s.

Factor VIII 2500 units and tranexamic acid 1 g were administered intravenously. Patient was endotracheally intubated, and anesthesia was maintained with oxygen, isoflurane and intermittent boluses of vecuronium. Left fronto temporal craniotomy and evacuation of about 30 ml of clot was performed. Patient was hemodynamically stable throughout the procedure with minimal blood loss. Mannitol and phenytoin were administered to optimize intracranial pressure and for seizure

## From:

<sup>1</sup>Departments of Anaesthesiology and <sup>4</sup>General Surgery, Institute of Medicine, Tribhuvan University Teaching Hospital, <sup>3</sup>Department of Internal Medicine, Civil Service Hospital, Kathmandu, <sup>2</sup>Department of Anaesthesiology, Alka Hospital Pvt. Ltd., Jawalakhel, Lalitpur, Nepal

## Correspondence:

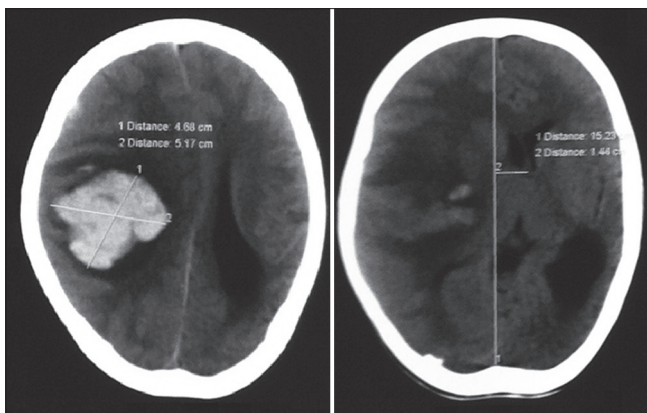
Dr. Gentle Sunder Shrestha, Department of Anaesthesiology, Tribhuvan University Teaching Hospital, Institute of Medicine, Maharajgunj, Kathmandu, Nepal. E-mail: [gentlesunder@hotmail.com](mailto:gentlesunder@hotmail.com)

prophylaxis respectively. Patient was electively kept on postoperative mechanical ventilation. Repeat CT scan of head 6 h after surgery revealed satisfactory evacuation of hematoma. Patient was extubated on 1<sup>st</sup> postoperative day. His postextubation GCS was 15. Factor VIII was administered at the dose of 2000 Units intravenously every 12 h for 3 days; 1250 units intravenously every 12 h for next 4 days and then 750 units intravenously every 12 h for next 7 days. Tranexamic acid was continued at 500 mg 4 times daily for 15 days. He was discharged home on 9<sup>th</sup> post-operative day.

**Case 2**

A 12-year-old male patient, weighing around 30 kg, a diagnosed case of hemophilia B, presented with decrease in the level of consciousness and decreased movement in the left half of the body. His GCS was 10 (E3 V2 M5). Pupil was 5 mm in right and 3 mm in left. CT scan revealed right fronto-parietal hematoma with significant midline shift [Figure 1]. His APTT was 86 s.

Recombinant Factor Ix 3500 Units and Tranexamic acid 1 g were administered intravenously, and patient was transferred to the operating room for an emergency craniotomy. Endotracheal intubation was done and anesthesia was maintained with oxygen, isoflurane and intermittent boluses of vecuronium. Right fronto temporal craniotomy was done, and clot was evacuated. Intraoperative blood loss was around 500 ml and one unit of crossmatched whole blood was transfused. Patient was electively kept on postoperative mechanical ventilation. Postoperative CT scan revealed some residual clots but with satisfactory resolution of midline shift and decrease in mass effect. Patient was extubated on 1<sup>st</sup> postoperative day. His postextubation GCS was 15. He had persistent left sided weakness which improved during the subsequent days of hospital stay.



**Figure 1:** Right fronto-parietal intracerebral hematoma (4.68 × 5.17 cm) with midline shift of 1.46 cm

Factor IX was administered at 3500 Units daily for first 3 days followed by 2000 Units daily for next 4 days and then 1500 Units daily for another 7 days. Tranexamic acid was continued intravenously at 500 mg 3 times daily for 15 days. Patient was discharged home on 10<sup>th</sup> postoperative day.

**Discussion**

Patients with severe hemophilia can present with spontaneous bleeding, commonly into joints and muscles.<sup>[4]</sup> Patients have high APTT, but platelet count, bleeding time and prothrombin time are normal. With the advancement in management of hemophilia, mortality rate of ICH has decreased. Replacement of deficient factors is the mainstay of treatment for bleeding episodes in patients with hemophilia.<sup>[5]</sup> Multidisciplinary team has to be involved when patients with hemophilia are planned for surgery. The knowledge related to replacement therapy should be mastered not only by hematologist, but also by the whole team involved in patient management.<sup>[6]</sup>

In patients with central nervous system bleeding, factor replacement is recommended for 14-21 days, depending on resource constraints as mentioned in Table 1. Each unit of FVIII per kilogram of body weight will raise the plasma level approximately 2 IU dL<sup>-1</sup>. Similarly, each unit of recombinant FIX per kilogram of body weight will raise the plasma level approximately 0.7 IU dL<sup>-1</sup> in children under 15 years of age.<sup>[4]</sup> Conservative factor replacement therapy coupled with antifibrinolytic agents was found to yield mortality similar to that of the western countries and with almost no morbidity.<sup>[2]</sup> In both cases, clotting factor was administered as recommended for places with significant resource constraints and tranexamic acid was administered for 15 days. Factor level measurement and testing for inhibitor was not performed due to financial constraints and limited availability of tests.

**Table 1: Suggested plasma factor peak level and duration of administration**

	No significant resource constraint		With significant resource constraint	
	Desired level (IU dL <sup>-1</sup> )	Duration (days)	Desired level (IU dL <sup>-1</sup> )	Duration (days)
Hemophilia A				
Initial	80-100	1-7	50-80	1-3
Maintenance	50	8-21	30-50	4-7
	-	-	20-40	8-14
Hemophilia B				
Initial	60-80	1-7	50-80	1-3
Maintenance	30	8-21	30-50	4-7
	-	-	20-40	8-14

Patients with spontaneous ICH with GCS Score of 8 or less might be considered for intracranial pressure monitoring.<sup>[7]</sup> Significant coagulopathy being contraindications for external ventricular drain placement, it was not performed in the first case. In a large trial, patients with hematomas extending to within 1 cm of the cortical surface, with GCS score of 9-12 had a trend towards more favorable outcome with early surgery.<sup>[8]</sup> Craniotomy for supratentorial ICH more than 30 ml, when performed early was associated with good outcome.<sup>[9]</sup> As both the patients had superficial clots with mass effect and a significant clot volume, emergency craniotomy with evacuation of clot was performed.

During the perioperative period, supportive measures for prevention of secondary brain injury like management of blood pressure, glucose, temperature, antiepileptic drugs, hyperosmotic agents, optimization of oxygenation and ventilation and securing of the airway were considered in both cases by a neurointensivist. Introduction of neurointensivist coordinated neurocritical care team is associated with a significant reduction of in-hospital mortality and length of stay.<sup>[10]</sup>

To conclude, even in resource constrained places, timely management of hemophilic patients with spontaneous intracerebral hemorrhage by a multidisciplinary team can improve the outcome.

## References

1. Fauci AS, Braunwald E, Kasper DL, Hauser SL, Longo DL,

Jameson JL, *et al.* Coagulation disorders. In: Arruda V, High KA, editors. *Harrison's Principles of Internal Medicine*. 17<sup>th</sup> ed. United States of America: McGraw-Hill; 2008. p. 725-31.

2. Ghosh K, Nair AP, Jijina F, Madkaikar M, Shetty S, Mohanty D. Intracranial haemorrhage in severe haemophilia: Prevalence and outcome in a developing country. *Haemophilia* 2005;11:459-62.

3. Hoots WK. Emergency care issues in hemophilia. In: Schulman S, editor. *Treatment of Hemophilia*. Montreal: World Federation of Hemophilia (WFH); 2007. p. 43.

4. Srivastava A, Brewer AK, Mauser-Bunschoten EP, Keys NS, Kitchen S, Lilinas A, *et al.* Guidelines for the management of hemophilia. *Haemophilia* 2013;19:e1-47.

5. Coppola A, Di Capua M, Di Minno MN, Di Palo M, Marrone E, Ieranò P, *et al.* Treatment of hemophilia: A review of current advances and ongoing issues. *J Blood Med* 2010;1:183-95.

6. Flores RP, Bagatini A, Santos AT, Gomes CR, Fernandes MS, Molon RP. Hemophilia and anesthesia. *Rev Bras Anesthesiol* 2004;54:865-71.

7. Morgenstern LB, Hemphill JC 3<sup>rd</sup>, Anderson C, Becker K, Broderick JP, Connolly ES Jr, *et al.* Guidelines for the management of spontaneous intracerebral hemorrhage: A guideline for healthcare professionals from the American Heart Association/American Stroke Association. *Stroke* 2010;41:2108-29.

8. Mendelow AD, Gregson BA, Fernandes HM, Murray GD, Teasdale GM, Hope DT, *et al.* Early surgery versus initial conservative treatment in patients with spontaneous supratentorial intracerebral haematomas in the International Surgical Trial in Intracerebral Haemorrhage (STICH): A randomised trial. *Lancet* 2005;365:387-97.

9. Pantazis G, Tsitsopoulos P, Mihas C, Katsiva V, Stavrianos V, Zymaris S. Early surgical treatment vs conservative management for spontaneous supratentorial intracerebral hematomas: A prospective randomized study. *Surg Neurol* 2006;66:492-501.

10. Suarez JI, Zaidat OO, Suri MF, Feen ES, Lynch G, Hickman J, *et al.* Length of stay and mortality in neurocritically ill patients: Impact of a specialized neurocritical care team. *Crit Care Med* 2004;32:2311-7.

**How to cite this article:** Shrestha GS, Poudyal B, Bhattarai AS, Shrestha PS, Sedain G, Acharya N. Perioperative management of two cases of hemophilia with spontaneous intracerebral hemorrhage undergoing emergency craniotomy in resource constrained setup of Nepal. *Indian J Crit Care Med* 2014;18:754-6.

**Source of Support:** Nil, **Conflict of Interest:** None declared.