

A rare case of leptospirosis with isolated lung involvement

Vijay Kumar Agrawal, Abhishek Bansal, Meenu Pujani

Abstract

Leptospirosis is a zoonosis caused by a pathogenic spirochete "leptospira interrogans." Severe form of leptospira infection is usually associated with jaundice and renal involvement, leading to major hemorrhagic complications. Lung involvement can vary from subtle clinical features to deadly pulmonary hemorrhage and acute respiratory distress syndrome (ARDS). We recently managed a case of leptospirosis with isolated lung involvement as alveolar hemorrhage and ARDS. Our patient had acute febrile illness with respiratory symptoms associated with radiological picture of pulmonary hemorrhage. Patient was managed with noninvasive ventilation with high flow oxygen, antibiotic and pulse steroids therapy. In conclusion, leptospirosis can present with predominant pulmonary involvement, instead of the classical triad of Weil disease. High index of suspicion should be kept in acute febrile illness patients with respiratory symptoms and alveolar hemorrhage. Early diagnosis and management with oxygenation, antibiotics and immunosuppressants can prevent complications and mortality.

Keywords: Acute respiratory distress syndrome, immunosuppressants, leptospirosis, noninvasive ventilation, pulmonary hemorrhage

Access this article online

Website: www.ijccm.org

DOI: 10.4103/0972-5229.152765

Quick Response Code:



Introduction

Leptospirosis is caused by "leptospira interrogans." Usually it causes mild disease, but in a substantial number of cases multiple organs are involved (Weil's disease), leading to high case fatality rate. It has biphasic patterns of illness with acute or septicemic phase for 1-week followed by immune phase for another 1-week. Severe form with multi-organ involvement includes jaundice, renal failure, hepatic necrosis, pulmonary involvement and hemorrhagic diathesis. Isolated lung involvement with acute respiratory distress syndrome (ARDS) is very rare in severe leptospira infection. We recently managed a case of leptospirosis with isolated lung involvement in term of alveolar hemorrhage and ARDS.

Case Report

A 25 years female, who was agricultural field worker from the rural background was admitted with high grade fever with chills and severe body ache of 6 days duration and cough with breathlessness of 3 days duration. Her breathing difficulty increased rapidly, and she noted one episode of blood mixed sputum on day of hospitalization. On admission, she had low grade fever, hypotension (blood pressure 90/60 mmHg), sinus tachycardia, severe tachypnea and hypoxia (SpO₂ 64% on room air). Her chest examination revealed reduced air entry in bilateral bases with coarse crepts. Initial arterial blood gas revealed type 1 respiratory failure (pH - 7.47, PCO₂-22.6, HCO₃-16, PO₂-42). Laboratory investigations revealed Hb 7.9 g%, platelet counts 80,000/cmm, aspartate transaminase/alanine transaminase 93/56 with serum total bilirubin of 0.8 mg/dl and normal renal parameters. Chest X-ray showed bilateral heterogenous opacity in mid and lower zones [Figure1]. Her two-dimensional echo revealed mildly dilated right atria, right ventricle with normal left ventricular functions. Serum procalcitonin was negative. Her nasal swab

From:

Department of Critical Care Medicine and Pulmonology, Metro Heart Institute with Multispeciality, Faridabad, Haryana, India

Correspondence:

Dr. Vijay Kumar Agrawal, House No 966, First Floor, Sector 37, Faridabad, Haryana, India. E-mail: vkabtd@hotmail.com

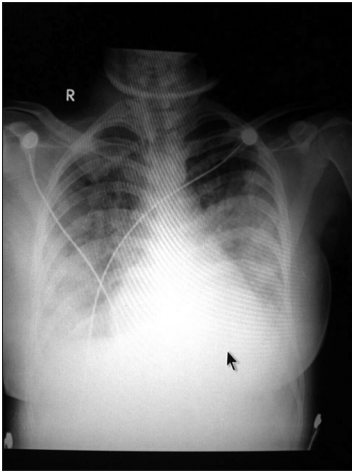


Figure 1: Chest X-ray

for H1N1 antigen, antinuclear antibody and Coomb's test were negative. She was managed with high flow oxygen along with noninvasive ventilation (NIV)/bilevel positive airway pressure (BiPAP) support, intravenous antibiotic (ceftriaxone), and vasopressors initially. High resolution computed tomography (HRCT) chest revealed bilateral mild pleural effusion with alveolar opacities in bilateral mid and lower zones with few areas of bronchial dilatation suggestive of alveolar hemorrhage. Serum IgM leptospira was done with ELISA method in view of radiological finding of alveolar hemorrhage and negative procalcitonin test, H1N1 antigen from nasal swab, antinuclear antibody and Coombs test. Serum IgM leptospira test revealed high positive value (>100 u/ml, negative <15 u/ml). She received pulse steroid therapy with methyl-prednisolone. In next 48 h her fever subsided, and breathlessness reduced. Her oxygen and BiPAP support reduced, and all parameters became normal in next 5 days. Her chest X-ray cleared and she was discharged in healthy state.

Discussion

Leptospirosis has been under-reported and under-diagnosed from India. The disease has been reported from various states during monsoon months in mini epidemics. The incidence of leptospirosis in developing countries is 10–100/100,000 cases/year. By this estimate, India should report 0.1–1.0 million cases per year, but <10,000 cases are reported.^[1-3]

The clinical expression of leptospira infection is related to diverse focal organ dysfunction includes subclinical infection, an undifferentiated febrile illness and Weil's disease-the most severe form. Severe form is usually associated with jaundice and renal involvement leading to major hemorrhagic complications. Lung

involvement can vary from subtle clinical features to deadly pulmonary hemorrhage and ARDS. Pulmonary involvement usually occurs in immune phase and the overt pulmonary manifestations occurs in 20–70% of patients, most of which resolve without any sequelae.^[4] Isolated lung involvement is rare and leads to the delayed diagnosis.

Pulmonary involvement can manifest clinically as cough, dyspnea, chest pain, and hemoptysis. Alveolar hemorrhage is the main pulmonary manifestation, which may vary from mild to severe, severity being related to mortality.^[5] Possible mechanism in alveolar hemorrhage is toxin mediated process leading to vascular injury, particularly small vessel vasculitis. The possible toxins include membrane glycoproteins, lipopolysaccharides, outer membrane proteins and hemolysins. Cytokines, like tumor necrosis factor-alpha may also be involved in the pathogenesis of leptospirosis.^[6] Vasculitis primarily affects capillaries leading to hemorrhage in alveoli. Other than toxin mediated process, another indirect pathogenic mechanism is host immune response to infection.^[5] Production, of circulating antibodies against the pathogen's lipopolysaccharides, leads to activations of innate immune system, which is initiating event in antibody generation.^[7] Severe pulmonary hemorrhage has a rapid and severe course with high mortality rates (30–60%).^[8] Rarely patients of leptospirosis may develop ARDS, and has a high mortality rate (up to 51%).^[9] ARDS is usually associated with pulmonary hemorrhage due to endothelial damage.^[8] Microscopic examination in severe pulmonary involvement reveals intra-alveolar and interstitial hemorrhage, pulmonary edema, fibrin deposition, hyaline membrane formation and proliferative fibroblastic reaction. Clavel *et al.* also reported a case of young female with leptospirosis, who presented as recurrent hemoptysis and ARDS without involvement of renal dysfunction and normal hepatic enzymes. Open lung biopsy in their case revealed typical lesion of bronchiolitis obliterans without inflammatory cells.^[10]

Diagnosis can be confirmed by either an isolation of the organism from blood and/or cerebrospinal fluid or seroconversion or a rise in antibody titer in the microscopic agglutination test. Other causes of alveolar hemorrhage like Wegener's granulomatosis, microscopic polyangiitis, good pasture syndrome etc., should be ruled out with appropriate history and investigations. Bronchoscopy with bronchoalveolar lavage may identify hemorrhage which may otherwise remain occult. Chest X-ray findings reveal rapidly evolving predominantly peripheral diffuse nodular or confluent pulmonary

lesions. HRCT findings are predominantly consisted of extensive ground glass opacities, predominantly afflict the peripheral and dorsal lung regions and the lower lung zones.

In management, most of the patients of leptospirosis show spontaneous recovery and do not require any specific therapy. Although, the use of antibiotics is not well proven in leptospirosis, its early initiation can shorten the course of severity and prevent the progression of mild disease.^[11] Penicillin, tetracycline, ceftriaxone and doxycycline are the preferred antibiotics. A Cochrane systematic review failed to find sufficient evidence to provide clear guidelines for use of antibiotics.^[12] Patients with severe leptospirosis require correction of hypovolemia, hypotension and electrolyte abnormalities. Management of respiratory failure should be done with timely initiation of mechanical ventilation with positive end-expiratory pressure or NIV (BiPAP) and high concentration of inspired oxygen. Extracorporeal membrane oxygenator has been used in refractory hypoxia cases.

Immunomodulation such as gluco-corticoids, immunoglobulin or plasmapheresis, may be helpful in severe leptospirosis. Several reports from India have supported use of glucocorticoids in leptospiral pulmonary hemorrhage.^[13,14] Shenoy *et al.* evaluated the efficacy of bolus methylprednisone and concluded that use of corticosteroids reduced the need for ventilator support only if given within first 24 h of onset of pulmonary symptoms; however the mortality benefit was not passed on to patients already on mechanical ventilation.^[14] The usefulness of cyclophosphamide and plasma exchange in patients with leptospiral pulmonary hemorrhage were studied by Trivedi *et al.*^[15] Inhaled nitric oxide, desmopressin, hemofiltration and activated factor VII are few of the novel approaches which have been tried in resistant cases of leptospirosis.^[16]

To conclude, leptospirosis is under-reported and under-diagnosed from developing countries like India. Severe leptospirosis may lead to isolated lung involvement or ARDS in the absence of jaundice and renal dysfunction. High index of suspicion should be kept in risk group involving population who work with infected animals, either directly or indirectly by contaminated

water or soil. Isolated lung involvement can present with acute febrile illness with respiratory symptoms and alveolar hemorrhage on radiological or bronchoscopic evaluation. Early diagnosis and management with oxygenation, antibiotic and immunosuppressants can prevent complications and mortality.

References

1. Shivakumar S. Leptospirosis-current scenario in India. In, Bichile SK. Ed. API Medicine Update, Mumbai 2008;18:799-809.
2. Kamath SA, Joshi SR. Re-emerging of infections in urban India – focus leptospirosis. *J Assoc Physicians India* 2003;51:247-8.
3. Pappas G, Papadimitriou P, Siozopoulou V, Christou L, Akritidis N. The globalization of leptospirosis: Worldwide incidence trends. *Int J Infect Dis* 2008;12:351-7.
4. Carvalho CR, Bethlem EP. Pulmonary complications of leptospirosis. *Clin Chest Med* 2002;23:469-78.
5. Bharti AR, Nally JE, Ricaldi JN, Matthias MA, Diaz MM, Lovett MA, *et al.* Leptospirosis: A zoonotic disease of global importance. *Lancet Infect Dis* 2003;3:757-71.
6. Estavoyer JM, Racadot E, Couetdie G, Leroy J, Grosperin L. Tumor necrosis factor in patients with leptospirosis. *Rev Infect Dis* 1991;13:1245-6.
7. Werts C, Tapping RI, Mathison JC, Chuang TH, Kravchenko V, Saint Girons I, *et al.* Leptospiral lipopolysaccharide activates cells through a TLR2-dependent mechanism. *Nat Immunol* 2001;2:346-52.
8. Nicodemo AC, Duarte MI, Alves VA, Takakura CF, Santos RT, Nicodemo EL. Lung lesions in human leptospirosis: Microscopic, immunohistochemical, and ultrastructural features related to thrombocytopenia. *Am J Trop Med Hyg* 1997;56:181-7.
9. Vieira SR, Brauner JS. Leptospirosis as a cause of acute respiratory failure: Clinical features and outcome in 35 critical care patients. *Braz J Infect Dis* 2002;6:135-9.
10. Clavel M, Lhéritier G, Weinbreck N, Guerlin A, Dugard A, Denes E, *et al.* Leptospirosis: An unusual cause of ARDS. *Crit Care Res Pract* 2010;2010:408365.
11. Brett.Major DM, Coldren R. Antibiotics for leptospirosis. *Cochrane Database of Systemic Review* 2012;2:CD008264
12. Guidugli F, Castro AA, Atallah AN. Antibiotics for treating leptospirosis. *Cochrane Database Syst Rev* 2000;2:CD001306.
13. Trivedi SV, Chavda RK, Wadia PZ, Sheth V, Bhagade PN, Trivedi SP, *et al.* The role of glucocorticoid pulse therapy in pulmonary involvement in leptospirosis. *J Assoc Physicians India* 2001;49:901-3.
14. Shenoy VV, Nagar VS, Chowdhury AA, Bhalgat PS, Juvale NI. Pulmonary leptospirosis: An excellent response to bolus methylprednisolone. *Postgrad Med J* 2006;82:602-6.
15. Trivedi SV, Vasava AH, Bhatia LC, Patel TC, Patel NK, Patel NT. Plasma exchange with immunosuppression in pulmonary alveolar haemorrhage due to leptospirosis. *Indian J Med Res* 2010;131:429-33.
16. Wakabayashi Y, Kamijou Y, Soma K, Ohwada T. Removal of circulating cytokines by continuous haemofiltration in patients with systemic inflammatory response syndrome or multiple organ dysfunction syndrome. *Br J Surg* 1996;83:393-4.

How to cite this article: Agrawal VK, Bansal A, Pujani M. A rare case of leptospirosis with isolated lung involvement. *Indian J Crit Care Med* 2015;19:174-6.

Source of Support: Nil, **Conflict of Interest:** None declared.