



A case of misplaced permacath dialysis catheter

Mohammed Arshad Ali, Kishore Raikar, Asha Kishore

Abstract

Central venous placement using ultrasound has significantly reduced the complications associated with blind puncture. The central venous catheter can still get misplaced if it follows an anomalous route after appropriate puncture of desired vessel. We report a case of misplaced dialysis catheter into the accessory hemiazygos vein which resulted in a large hemothorax, and we recommend the routine use of a fluoroscope for placement of dialysis catheters so as to avoid serious complications.

Keywords: Accessory hemiazygos vein, hemothorax, permacath, ultrasound

Access this article online

Website: www.ijccm.org

DOI: 10.4103/0972-5229.162473

Quick Response Code:



Introduction

Central line placement is associated with risk of inadvertent puncture of the artery, pleura, and other nearby structures. These risks have been very much reduced with the use of point of care ultrasound. Even though ultrasound can guide proper puncture of the vessel desired, it cannot help in following or directing the course of the catheter after venepuncture. Misplacement of a large catheter such as the dialysis catheter can have serious consequences. We report here a case of misplaced dialysis catheter into the accessory hemiazygos vein.

Case Report

A 63-year-old woman, known case of chronic renal failure was admitted to the hospital for urgent dialysis. Her serum creatinine was 1444 $\mu\text{mol/L}$, and her blood urea nitrogen was 48.7 mmol/L . Her serum potassium was 6.2 mmol/L . She was mentally retarded with aggressive behavior. She had had dialysis catheter placed many times which she had pulled out during her bursts of aggressive behavior. Arteriovenous fistula was done one time which also failed. This time she presented without a dialysis catheter. We decided to place a

permacath in the operation theater. She was given light general anesthesia. We chose the internal jugular as the vein of choice for the procedure. With the ultrasound, we assessed her internal jugulars. Her previous tunneled catheter which she had pulled out before was in the right internal jugular. This time the right internal jugular could not be visualized at all with ultrasound. It was presumed that either it was thrombosed or hidden in the fibrosis of the surrounding soft tissues. The left internal jugular was visible clearly. Under sterile precautions, it was punctured under ultrasound guidance, and the guide wire was passed. There was a slight difficulty in passing the guide wire but after some manipulation it passed. There were no ectopics in the electrocardiogram when the guide wire was passed. Ultrasound was used and guide wire was identified as a bright speck inside the internal jugular vein (IJV) in short axis. Fluoroscope was not used as it was engaged in some other case. Having clearly confirmed the guide wire presence in the IJV, we decided to proceed further. The dialysis catheter was tunneled from a suitable site in her chest. A peel away introducer was passed over the guide wire, and the wire removed. Typical venous blood was observed exiting from the introducer and the permacath was passed as the introducer was peeled off. Typical venous blood was aspirated from both permacath lumens and lumens were flushed and closed with heparin lock. The procedure seemed uneventful, and the patient was made awake. A routine portable X-ray was ordered before shifting the patient to the dialysis unit. When we saw the X-ray,

From:

Department of Anesthesiology and Intensive Care, Dibba Hospital, UAE

Correspondence:

Dr. Mohammed Arshad Ali, Department of Anaesthesiology and Intensive Care, Dibba Hospital, P.O. Box 11414, UAE.
E-mail: faryas99@yahoo.com

we were shocked to find the catheter entirely in the left side of the heart as though it had passed through the aorta [Figure 1]. We took the patient back to occupational therapy and connected a transducer to the catheter port which showed a venous waveform. A blood gas analysis of the aspirated blood also showed venous values. Anyhow it was decided to leave the catheter untouched at that time as the patient was unstable. We urgently placed a regular dialysis catheter in her right femoral vein, and she was sent for dialysis. After 3 days of dialysis, the patient became stable and computed tomography (CT) chest was done. The preliminary X-ray done during CT clarified the position of the catheter in the lateral edge of aortic knuckle [Figure 2], which is the location of left superior intercostal vein. The reconstructed coronal and sagittal CT images [Figures 3 and 4] showed the catheter tending to go into the accessory hemiazygos vein which communicates with the left superior intercostal vein. The X-ray and CT films also showed large hemothorax on the left side which suggested that the veins were partially

damaged by the large catheter. As the patient was very stable, we just removed the catheter and applied pressure dressing at the entry site. The patient tolerated it without any problems. The hemothorax was kept under observation as the patient did not have any respiratory distress, and the relatives did not give consent for chest tube insertion. The hemothorax was persistent but not increased in size. After another 3 days, once consent was obtained, we inserted an intercostal drainage (ICD) tube on the left side and drained about 1500 mL of altered blood. The lung expanded completely, and the ICD was removed. The patient was safely discharged subsequently.

Discussion

A catheter passing through left brachiocephalic has a chance of taking 3 anomalous routes. One is the left superior intercostal vein,^[1] which communicates with accessory hemiazygos^[2] as in our case. The other

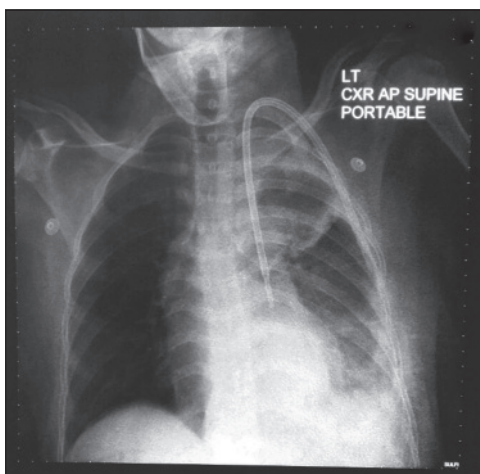


Figure 1: Permacath seen in the left side of the heart

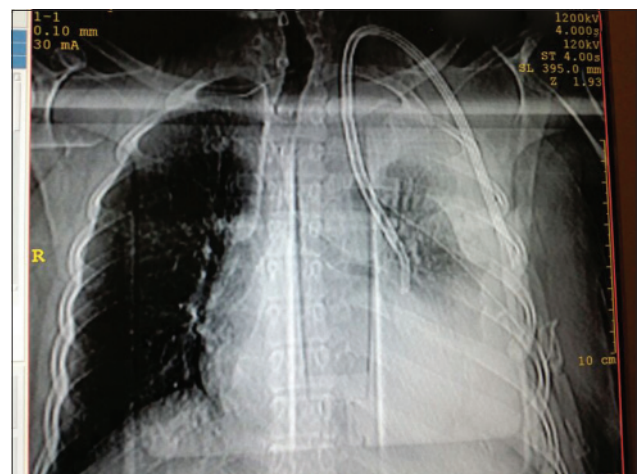


Figure 2: Large pleural effusion on left side

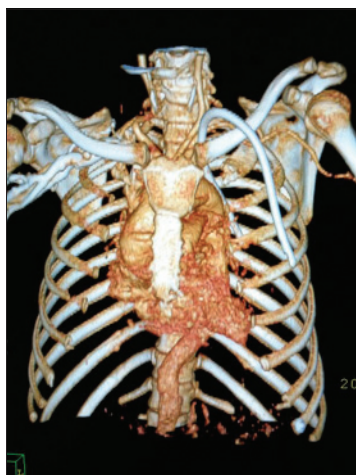


Figure 3: Reconstructed coronal computed tomography showing permacath outside heart presumably in left superior intercostal vein

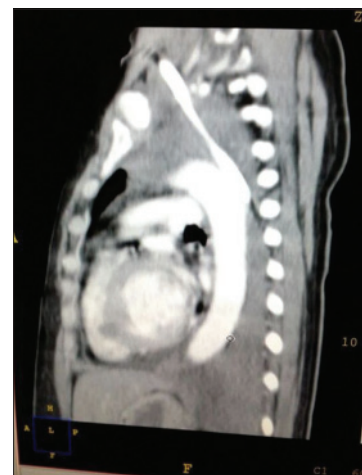

Figure 4: Sagittal reconstructed computed tomography showing permacath behind aorta

is left internal thoracic vein^[3] which runs anterior to the aortic knuckle. One other possibility is the pericardiophrenic vein^[4] which runs along the lateral cardiac border. Misplaced central lines in all these locations have been reported and have not usually resulted in serious consequences except in the case of pericardiophrenic vein. Misplacement of the large dialysis catheter in these locations has been reported^[5,6] and can have dangerous consequences like hemothorax, pneumothorax, hemopericardium, cardiac tamponade, etc. Even though entry of the catheter into a planned vein can be ensured using ultrasound, its subsequent passage cannot be controlled.

References

1. Padovan RS, Paar MH, Aurer I. (Mis) placed central venous catheter in the left superior intercostal vein. *Radiol Oncol* 2011;45:27-30.
2. Smith DC, Pop PM. Malposition of a total parenteral nutrition catheter in the accessory hemiazygos vein. *JPEN J Parenter Enteral Nutr* 1983;7:289-92.
3. Moeinipour AA, Amouzeshi A, Jouidi M, Fathi M, Jahanbakhsh S, Hafez S, *et al.* A rare central venous catheter malposition: A case report. *Anesth Pain Med* 2014;4:e16049.
4. Damon I, Masaki MD, Jeffrey S, Grenspoon MD. Cardiac tamponade from central venous line placement. *Arch Intern Med* 1989;149:972.
5. Sarnak MJ, Levey AS. Placement of an internal jugular dialysis catheter into the superior intercostal vein. *Nephrol Dial Transplant* 1999;14:2028-9.
6. Ghafoor H, Fatimi Sh, Ali M. Unusual malposition of dialysis catheter in the left internal mammary vein – A case report. *Middle East J Anaesthesiol* 2011;21:139-41.

How to cite this article: Ali MA, Raikar K, Kishore A. A case of misplaced permacath dialysis catheter. *Indian J Crit Care Med* 2015;19:490-2.

Source of Support: Nil, **Conflict of Interest:** None declared.