

# Managing iatrogenic tracheal injuries

C. D. A. Goonasekera, S. T. Esufali<sup>1</sup>

## Abstract

We present three cases of iatrogenic tracheal injury. Two patients suffered acute tracheal injuries during anesthesia/surgery, one was managed surgically and the other conservatively. The third case is a delayed tracheal injury presenting as a fistula. The reasons for surgical vs conservative management of tracheal injuries and preventive measures are discussed.

**Key Words:** Clinical management, Endotracheal intubation, Iatrogenic, Tracheal injury

## Introduction

Tracheal integrity is essential for normal respiration. Hence any injury or obstruction to the trachea seriously jeopardizes life. It is also easily accessible for therapeutic maneuvers such as oral or nasal intubation using tubes with inflatable cuffs that prevents leak of air and aspiration of fluids and other debris and tracheotomy. With increased use of artificial ventilation for anesthesia and prolonged respiratory support in intensive care, endotracheal intubation has become the most popular method utilized for control and maintenance of the airway. We are presenting here three case reports of tracheal injury following endotracheal intubation.

## Case History

### Case 1

A 52-year-old previously healthy female underwent a transhiatal oesophagectomy under general anesthesia for esophageal carcinoma. Her airway was secured with a cuffed 7.5 mm endotracheal tube and she was managed with positive pressure ventilation using a volume-

preset ventilator. During dissection of the esophagus, a hissing noise was heard at the neck incision with loss of airway pressure suggesting a large leak of air through a tracheal tear. The ventilation and oxygenation of the patient could now only be instituted by occlusion of the tear by the surgeon's finger and subsequently by a surgical gauze swab. Whilst maintaining lung ventilation with 100% oxygen and anesthesia with inhaled 0.75% halothane, a 4 cm longitudinal tear in the right-posterior wall of the trachea was identified just proximal to the bifurcation and repaired with a continuous nylon suture ensuring a seal, via right lateral thoracotomy.

Immediately postoperatively she was allowed spontaneous breathing with humidified 40% oxygen inhalation via a 'T' piece (without CPAP) attached to her endotracheal tube in the intensive care unit (ICU). Adequate analgesia was maintained by morphine infusion (1–2 mg/h) and a total of 4 units of blood were transfused and hydration maintained using intravenous saline/dextrose. Peripheral pulse oximeter oxygen saturation (SpO<sub>2</sub>) of 95% and comfort was achieved with this management although patient remained intubated. Urine output was adequate (over 1 ml/kg/h).

She became exhausted from work of breathing at 72 h along with an increase in her oxygen requirement (FiO<sub>2</sub>

**From:** Departments of Anesthesiology and <sup>1</sup>Surgery, Teaching Hospital, Peradeniya, Sri Lanka

**Correspondence:** Dr CDA Goonasekera, Department of Anesthesiology, Faculty of Medicine, Peradeniya, Sri Lanka. E-mail: cgoonase@slt.lk

Free full text available from [www.ijccm.org](http://www.ijccm.org)

60%). Intermittent positive pressure ventilation was instituted immediately with a low-tidal volume (260 ml), high-respiratory rate (30/min), and low-normal range peak airway pressure (20 cm water). Radiologically there was no pneumothorax or pneumomediastinum. Blood for D-dimers was negative. Her lung function improved within 12 h and mechanical ventilation was discontinued after 36 h. She was extubated on the fifth postoperative day and since made an uneventful recovery.

### Case 2

A 47-year-old healthy female developed swelling of face and difficulty in breathing and chest pain within 2 h of a vaginal hysterectomy performed under general anesthesia in a peripheral hospital. She had been intubated using a cuffed endotracheal tube during surgery. Her ECG was normal except for a sinus tachycardia and her swelling of face was due to surgical emphysema [Figure 1]. Following transfer to a tertiary care center, she was given pethidine and promethazine for pain relief. Her respiratory rate was 24–26/min. She needed 40% oxygen via facemask to maintain a peripheral SpO<sub>2</sub> of 95%. Her respiratory observations were stable and hence, she was managed conservatively. A course of intravenous ampicillin and metronidazole was given. After 72 h her facial swelling began to subside. She was also pyrexial postoperatively. On the fourth day, she was afebrile and was no longer breathless. She has made an uneventful recovery since.

### Case 3

A 22-year-old female presented with a chronic produc-

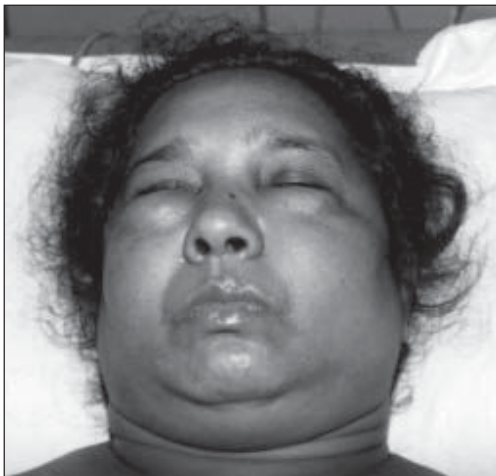

Figure 1: Swelling of the face and neck due to surgical emphysema appearing a few hours following tracheal tear

tive cough of 3-month duration not responsive to several courses of antibiotics, physiotherapy, and bronchodilators. This cough had originated following her stay in another hospital previously with pesticide poisoning for which she had received intensive care therapy constituting artificial respiratory support for 22 days. During this time she had been intubated. A dilute barium swallow was attempted but failed due to severe coughing spasms. At upper gastro intestinal endoscopy tracheal rings could be visualized through a hole in the esophageal wall a few centimeters distal to the upper esophageal sphincter.

She was operated under general anesthesia but could be intubated only with a 5.5 mm endotracheal tube due to a narrowing in the mid-tracheal region. This cuffed endotracheal tube was placed just at carina bypassing the fistula opening [Figure 2] ensuring adequate ventilation of both lungs. The tracheal opening and esophageal opening were closed longitudinally independently with interrupted nylon sutures whilst the endotracheal tube and a nasogastric tube were *in situ*. The mobilized and divided sternomastoid muscle flap was folded and interposed between the tracheal and esophageal suture lines.

Postoperatively she was managed in the ICU, whilst intubated with spontaneously breathing 40% oxygen via a 'T' piece, regular tracheal suction, and chest physiotherapy. The endotracheal tube was removed on the fourth day and the naso-gastric tube on the sixth day postoperatively. Her voice was preserved and there was no stridor at follow up. Her coughing spasms and recurrent chest infections had resolved.




Figure 2: A large tracheo-oesophageal fistula resulting from long-term tracheal intubation as demonstrated during corrective surgery

## Discussion

Airway rupture during surgery as described in case 1 may trigger a cascade of immediate life-threatening complications, namely inadequate alveolar ventilation, development of a pneumothorax/pneumomediastinum, and a reduction in cardiac output if the latter was under tension.<sup>[1,2]</sup> Acute asphyxia may follow esophageal wall prolapse into tracheal lumen. The best course of action, therefore, would be an immediate repair with the intermittent packing technique to control air leaks as described. The reported incidence of iatrogenic tracheo-bronchial lacerations during thoracic procedures is variable (0.37–7.1%)<sup>[3,4]</sup> and are usually either 'popping injuries' following undue inflation of the cuff, or 'ploughing injuries' caused by a stylet, the tip of the catheter, or a carinal spur.

Major airway injuries are usually managed preserving spontaneous respiration and some suggest an elective tracheotomy to reduce build up of airway pressure,<sup>[5]</sup> which may encourage passage of air and secretions through the tear into the mediastinum. Coughing, valsalva maneuver, sneezing, laughing, and speaking loudly also significantly increase the tracheal pressure leading to a repetitive fissure margin split that frustrates the healing process, thus predisposing to fistula formation. Occasionally there shall be no choice but to implement positive pressure ventilation as described in case 1 due to poor lung function. Under this circumstance lower peak airway pressure, low-tidal volume, and high-respiratory rate are strategies that may be used to reduce the risk of a re-opening airway leak. Rarely, conservative management of airway lacerations detected post-thoracotomy has been reported with a successful outcome.<sup>[6]</sup>

The dilemma of conservative vs surgical treatment arises when tracheal lacerations occur during nonthoracic surgical procedures due to direct trauma by stylet or over inflated tracheal cuff of the endotracheal tube or rapid rises in airway pressure as in an episode of violent cough seen in case 2. Such events are usually noted a few hours postoperatively when the patient continues to have unexplained coughing episodes, retrosternal chest pain, and appearance of surgical emphysema around the neck.<sup>[7]</sup> Such cases should be closely monitored. Some consider conservative treatment with cough suppression, antibiotics, and oxygen

therapy in such cases as done in our case 2 in the absence of airway compression. However, having a fiberoptic endoscopy assessment in such cases before a judgment is given for conservative approach is prudent. Massard et al. have reported two cases out of four on a watch-and-wait policy following tracheal rupture subsequent to intubation with successful results.<sup>[8]</sup> Endotracheal intubation may also produce large tracheal lacerations (9.5 cm) that may need primary surgical repair urgently and can only be diagnosed by emergency bronchoscopy.<sup>[9]</sup> Late diagnosis can be associated with sepsis, multiorgan failure, and high mortality.<sup>[7]</sup> Thus, bronchoscopy remains the diagnostic procedure of choice<sup>[10]</sup> under full relaxation (to avoid worsening of the laceration) before the conservative approach is considered.<sup>[7]</sup> The prognosis of tracheal lacerations depends not only on the speed of diagnosis and the mode of treatment but also on the general health of the patient<sup>[4]</sup> and the expertise of the anesthetists and surgeons and the experience of the center, and hence the need for them to be treated in a unit with experience in managing such injuries.

There is no place for conservative management of large lacerations (case 1) because failed medical treatment may reduce the chances of a successful delayed surgical repair due to infection and inflammation that inevitably follow.<sup>[3]</sup> Failure of conservative treatment (needing late repair) is usually due to the persistent passage of air and tracheo-bronchial secretions through the laceration into the mediastinum<sup>[5]</sup> leading to mediastinal emphysema, sepsis (acute 'mediastinitis'), and abscess formation, ventilatory difficulty, pseudo diverticular formation at the site of laceration and formation of fistulae. Acute 'mediastinitis' is a serious condition that has a rapid clinical course with high fever, pain in the chest, back or upper abdomen, dyspnea, tachycardia, and shock and is frequently fatal. Immediate repair of the perforation, wide drainage, broad spectrum antibiotics, and supportive care is the main stay of treatment.

Longitudinal laceration of the membranous portion of the trachea is considered unlikely to produce late stenotic lesions whereas circumferential ischemic necrosis of airway cartilage and subsequent retraction during the scarring process,<sup>[11]</sup> for example, postintubation or post-tracheotomy as reported in case 3 is more likely to do so especially if inflated cuff pressure exceeds 30 cm of

water. This ischemia produces tracheal mucosal necrosis, which if persistent can erode into the posterior wall and subsequently into the esophagus leading to formation of a fistula. This is probably the etiology of formation of fistula in case 3. It is now recommended that tracheal cuff pressures should be monitored during anesthesia and prolonged intubation in ICUs using a special device and should be maintained less than 25 cm of water.

Tracheal intubation should not be taken lightly as the complications are life threatening and hence should involve trained personnel. Monitoring cuff pressures should be considered mandatory to avoid problems of over-inflated cuff leading to tracheal rupture or late tracheal injury due to ischemia or pressure alone. If a tracheobronchial rupture is suspected, immediate further investigation by fiberoptic bronchoscopy is needed, as delayed diagnosis is associated with a poorer prognosis.

### References

1. Rushman GB, Davies NJ, Cashman JN. The administration of volatile anaesthetics and gases; *In: Lee's Synopsis of Anaesthesia*, Butterworth Heinemann: Oxford; 1999. p. 152-73.
2. Rushman GB, Davies NJ, Cashman JN. Surgical operations and choice of anaesthetic; *In: Lee's Synopsis of Anaesthesia*. Butterworth Heinemann: Oxford; 1999. p. 385-492.
3. Spaggiari L, Rusca M, Carbognani P, Solli P. Tracheobronchial laceration after double-lumen intubation for thoracic procedures. *Ann Thorac Surg* 1998;65:1837-8.
4. Massard G, Rouge C, Dabbagh A, Kessler R, Hentz J, Roeslin N, *et al.* Tracheobronchial lacerations after intubation and tracheostomy. *Ann Thorac Surg* 1996;61:1483-7.
5. Nazari S, Buniva P, Aluffi A, Salvi S, Mourad Z. Decompressing tracheostomy for the treatment of postintubation tracheal rupture. *Ann Thorac Surg* 1996;68:1121-7.
6. Personne C, Kleinmann P, Bisson A, Toty L. Les déchirures tracheobronchiques par sonde de Carlens. *Ann Chir* 1987;41:494-7.
7. Kaloud H, Smolle-Juettner F, Prause G, List WF. Iatrogenic ruptures of the tracheobronchial tree. *Chest* 1997;112:774-8.
8. Massard G, Wihlm J, Roeslin N, Frankhauser J, Hentz J, Dumont P, *et al.* Plaies tracheobronchiques iatrogenes au cours de l'intubation. 5 observations et revue de la litterature. *J Chir Paris* 1992;129:297-302.
9. Evagelopoulos N, Tossios P, Wanke W, Krian A. Tracheobronchial rupture after emergency intubation. *Thorac Cardiovasc Surg* 1999;47:395-7.
10. Berry M, Van-Schil P, Van-Meerbeeck J, Vanmaele R, Eyskens E. Surgical treatment of iatrogenic tracheal lacerations. *Acta Chir Belg* 1997;97:308-10.
11. Couraud L, Jougon J, Velly JF. Surgical treatment of nontumoral stenoses of the upper airway. *Ann Thorac Surg* 1995;60:250-9.