

Another cutaneous sign of acute pancreatitis

Sir,

A 45-year-old male who was a chronic alcoholic for 20 years was admitted in a state of shock. He had complaints of abdominal pain and vomiting for 10 days duration. There was history of constipation for 3 days. On examination, patient was semiconscious. Pulse rate and blood pressure was 112/min and 80/60 mmHg, respectively. Abdominal examination showed distended abdomen. On palpation, there was guarding and rigidity. On auscultation bowel sounds were absent. There was positive grey turner's sign (ecchymosis of flanks). Another new ecchymosis noted in the right axilla and was deep blue in color [Figure 1].

Investigations showed leukocytosis with elevated liver and renal function test. There was elevated amylase (890 U/L) and lipase (595 U/L) levels. Computed tomography of abdomen showed pancreatic necrosis with peripancreatic fluid collection and peripancreatic fat stranding [Figure 2]. He was diagnosed as acute necrotising pancreatitis. Aspirate negative for gram stain and culture and sensitivity. Hence, patient managed with intravenous fluid, proton pump inhibitor, ocerotide infusion, and inotropic support. In due course, he developed desaturation and was intubated. His condition improved with above measures. Ecchymosis in the right axilla started to fade during recovery period. After 15 days, there was a complete disappearance of ecchymosis in the right axilla.

A cutaneous manifestation of pancreatitis is very rare compared to abdominal signs. There are numerous cutaneous sign mentioned in pancreatitis. They are (1) Grey Turner's sign-ecchymosis of flanks, (2) Cullen's sign-ecchymosis around the umbilicus, (3) Fox's sign-ecchymosis of thigh, and (4) Bryant's sign-bluish discoloration of scrotum.^[1] Causes of Grey Turner's sign and Cullen's sign includes acute pancreatitis, hemorrhagic pancreatitis, retroperitoneal hemorrhage, blunt abdominal trauma, ruptured ectopic pregnancy, spontaneous bleeding following coagulopathy, ruptured aortic aneurysm, ruptured common bile duct, perforated duodenal ulcer, ruptured hepatocellular carcinoma, hepatic lymphoma, Percutaneous liver biopsy, and rectus sheath hematoma.^[2,3]

Etiology of Cullen's sign includes formation of methemalbumin in subcutaneous plane due to digested blood around the abdomen from the inflamed pancreas and the blood likely diffuse via the falciform ligament to the subcutaneous tissue around the

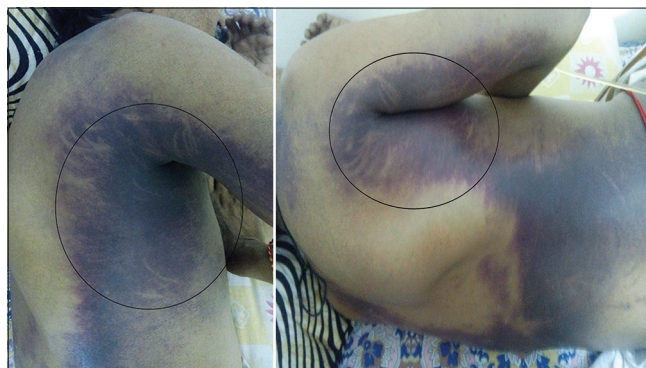

Figure 1: Ecchymosis noted in the right axilla which was deep blue in colour

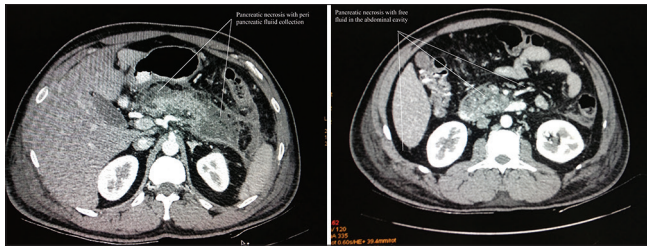


Figure 2: Computed tomography of abdomen showed pancreatic necrosis with peripancreatic fluid collection and peripancreatic fat stranding

umbilicus.^[4] Etiology of Grey Turner's sign is spread of the pancreatic inflammation from the anterior pararenal space between the posterior renal fascia and subsequently to the lateral edge of the quadratus lumborum muscle.^[5] Discoloration of skin in Grey Turner's sign or Cullen's sign varies from blue, purple, green, and yellow color.

In our case, there was an ecchymosis found the flanks (Grey Turner's sign) and one more ecchymosis found near the axilla. Axillary ecchymosis appeared as deep blue color. Etiology of ecchymosis in our case was probably due to formation of methemalbumin due to pancreatitis. Our patient had severe necrotising pancreatitis and developed systemic inflammatory response syndrome. Once patient recovered from pancreatitis, the lesion started to fade away. This ecchymosis over the axilla can help to diagnose pancreatitis early. It can also act as an indicator for severity of pancreatitis. It can be considered as a new sign in pancreatitis.

Financial support and sponsorship

Nil.

Conflicts of interest

There are no conflicts of interest.

Jayabal Pandiaraja

Department of General Surgery, SRM Medical College and Hospital, Chennai, Tamil Nadu, India

Correspondence:

Dr. Jayabal Pandiaraja,
26/1, Kaveri Street, Rajaji Nagar, Villivakkam,
Chennai - 600 049, Tamil Nadu, India.
E-mail: dr.pandiaraja@gmail.com

References

1. David M, Pelberg J, Kuntz C. Grey Turner's sign. QJM 2013;106:481-2.
2. Chhabra P, Rana SS, Sharma V, Sharma R, Bhasin DK. Grey Turner's sign in acute necrotizing pancreatitis. Ann Gastroenterol 2015;28:147.
3. Chung KM, Chuang SS. Cullen and Grey Turner signs in idiopathic perirenal hemorrhage. CMAJ 2011;183:E1221.
4. Rahbour G, Ullah MR, Yassin N, Thomas GP. Cullen's sign – Case report with a review of the literature. Int J Surg Case Rep 2012;3:143-6.
5. Masha L, Bernard S. Grey Turner's sign suggesting retroperitoneal haemorrhage. Lancet 2014;383:1920.

This is an open access article distributed under the terms of the Creative Commons Attribution-NonCommercial-ShareAlike 3.0 License, which allows others to remix, tweak, and build upon the work non-commercially, as long as the author is credited and the new creations are licensed under the identical terms.

Access this article online	
Quick Response Code: 	Website: www.ijccm.org
	DOI: 10.4103/0972-5229.182207

How to cite this article: Pandiaraja J. Another cutaneous sign of acute pancreatitis. Indian J Crit Care Med 2016;20:313-4.