

# Melioidosis: An Emerging Infection with Fatal Outcomes

Isabella Princess, R. Ebenezer<sup>1</sup>, Nagarajan Ramakrishnan<sup>2</sup>, Arun Kumar Daniel<sup>3</sup>, S. Nandini<sup>4</sup>, M. A. Thirunarayan<sup>4</sup>

Departments of Microbiology, <sup>1</sup>Critical Care Medicine and <sup>3</sup>Biochemistry, Apollo Speciality Hospitals, Vanagaram, <sup>2</sup>Departments of Critical Care Medicine and <sup>4</sup>Microbiology, Apollo Hospitals, Grems Road, Chennai, Tamil Nadu, India

## Abstract

According to the Centers for Disease Control and Prevention, from being nonendemic for melioidosis, India has now become endemic for the disease since 2012. Until then, melioidosis cases were being reported sporadically from India. There have been isolated case reports from few states across the country for the past few years. Most of the times, *Burkholderia pseudomallei* may be misreported as *Pseudomonas* species, especially in resource-poor laboratories. Due to its varied clinical presentation, the specific clinical diagnosis can be difficult, thereby making laboratory diagnosis mandatory. This could make a huge impact on patient care as this organism has a different treatment protocol as well as virulence determinants which influence the course of management. Although known for its endemicity in Australia, Thailand, and other Southeast Asian countries, *B. pseudomallei* has emerged in new areas such as India, Southern China, Brazil, and Malawi. We present a rare case of melioidosis with rapid disease progression to fatal outcome from Chennai, South India.

**Keywords:** *Burkholderia pseudomallei*, melioidosis, septic arthritis, septic shock

## INTRODUCTION

Emerging infections can be defined as “infections that have newly appeared in a population or have existed previously but are rapidly increasing in incidence or geographic range.”<sup>[1]</sup>

In present days, due to evolving lifestyle modifications, extensive travel, climate change, etc., diseases previously confined to specific countries have crossed their borders.<sup>[2]</sup> Increase in the number of cases of diabetes mellitus and other immunocompromised states have influenced increase in reports of emerging infections, namely melioidosis. Melioidosis is potentially fatal as early diagnosis is missed due to its varied manifestations such as localized or disseminated infection. Localized manifestations reported are pneumonia, multiple abscesses, septic arthritis, psoas abscess, gluteal abscess, scalp abscess, pericardial effusion, and supraclavicular mass.<sup>[3]</sup> It also mimics tuberculosis, and there have been reports of patients initially being treated for tuberculosis until a definitive diagnosis was made.<sup>[4]</sup> Musculoskeletal involvement manifests as osteomyelitis, septic arthritis, paraspinal abscess, arthritis of shoulder joints, and multiple joint swellings.<sup>[5,6]</sup> A recent report published in 2016 denotes that South Asian countries bear 44% of the overall burden of melioidosis.<sup>[7]</sup> In India, most cases of melioidosis have been reported from the western and eastern

coastal belts, thereby signifying a rich load of this bacterium in the environment, especially soil. Case reports from India have mainly emerged from Mangalore, Chennai, Pondicherry, Vellore, Hyderabad, and West Bengal.

## CASE REPORT

A 61-year-old male hailing from Pondicherry, South India, presented with a history of intermittent high-grade fever since 1 month, swelling of right knee joint since 1 month which was associated with severe pain, and inability to weight bear. He gave a history of inability to walk due to knee pain since 1 week. Patient was treated for right knee pain, swelling, and for urinary tract infection in another health-care facility before being referred to our hospital. Details of previous treatment are not known. He was a known case of type II diabetes mellitus on treatment for few months. Patient gave a history of sudden onset breathlessness since the evening before admission. On arrival at the emergency department,

**Address for correspondence:** Dr. Isabella Princess,  
Apollo Speciality Hospitals, Vanagaram,  
Chennai - 600 095, Tamil Nadu, India.  
E-mail: drisabella\_p@apollohospitals.com

### Access this article online

Quick Response Code:



Website:  
www.ijccm.org

DOI:  
10.4103/ijccm.IJCCM\_122\_17

This is an open access article distributed under the terms of the Creative Commons Attribution-NonCommercial-ShareAlike 3.0 License, which allows others to remix, tweak, and build upon the work non-commercially, as long as the author is credited and the new creations are licensed under the identical terms.

**For reprints contact:** reprints@medknow.com

**How to cite this article:** Princess I, Ebenezer R, Ramakrishnan N, Daniel AK, Nandini S, Thirunarayan MA. Melioidosis: An emerging infection with fatal outcomes. Indian J Crit Care Med 2017;21:397-400.

he was conscious, febrile, tachycardic, tachypnoeic, and hypotensive with reduced saturation. He had extensive bilateral crepitations.

On examination, patient had right knee swelling which was warm and tender. A provisional diagnosis of septic arthritis right knee with severe septicemia in septic shock and type 2 diabetes mellitus was made. In view of severe respiratory distress and hypotension patient was intubated, fluid resuscitated and was started on inotropes and vasopressors. Patient was transferred to critical care unit for further management, intravenous meropenem and teicoplanin were administered immediately. This empiric cover was chosen because patient on presentation had septic shock with hemodynamic instability and had been treated for past few days in an outside hospital with broad-spectrum antibiotics. Blood gas analysis revealed severe metabolic acidosis with lactic acidemia. Patient had anuria, and his baseline investigations revealed severe leukopenia, deranged liver function, renal function, and coagulation profile [Table 1]. These investigations were carried out during patient's admission to the Critical Care Unit. On the same day, patient developed ventricular tachycardia which was cardioverted. He subsequently developed bradycardia and was resuscitated with three cycles of cardiopulmonary resuscitation as per Advanced Cardiac Life Support protocol, but despite all efforts, he succumbed to the illness within 24 h of admission.

**Table 1: Laboratory investigations**

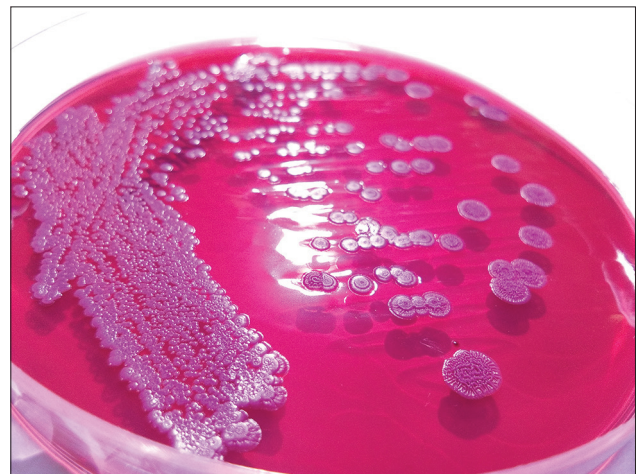Biochemical and hematological parameters	Value
Total serum bilirubin (mg/dL)	3.4
Conjugated bilirubin (mg/dL)	3.2
Total serum protein (g/dL)	5.9
Serum albumin (g/dL)	2.8
Serum globulin (g/dL)	3.1
SGOT (U/L)	198
SGPT (U/L)	230
Alkaline phosphatase (U/L)	422
Gamma-glutamyl transferase (U/L)	241
Random blood glucose (mg/dL)	367
Serum urea (mg/dL)	73
Serum creatinine (mg/dL)	1.8
ESR (mm/h)	114
Total WBC count (mm <sup>3</sup> )	2.53
Differential count (%)	
Neutrophils	92
Lymphocytes	6
Eosinophils	2
Microbiological investigations	Report
C-reactive protein (IU/ml)	≥192
Blood culture	<i>Burkholderia pseudomallei</i>
Widal	Titers not suggestive of enteric infection

SGOT: Serum glutamic oxaloacetic transaminase; SGPT: Serum glutamic pyruvic transaminase; ESR: Erythrocyte sedimentation rate; WBC: White blood cell

Blood culture was taken at the time of admission. Within 12 h of incubation in the BACTEC automated system, a Gram-negative organism with typical bipolar staining was observed on Gram stain. On blood agar, dry, wrinkled hemolytic colonies were seen. On MacConkey agar, dry, wrinkled colonies with metallic sheen were observed [Figure 1]. The organism was motile, oxidase positive, utilized citrate, and produced alkaline reaction on triple sugar iron agar. Based on the colony morphology and staining properties, upon suspicion of *Burkholderia pseudomallei*, antibiotic susceptibility testing was done for selective antibiotics according to CLSI 2016 M100S (26<sup>th</sup> edition) document. Polymyxin B minimum inhibitory concentration (MIC) was done by E-test and found to be resistant with no zone of inhibition. Antibiogram was also suggestive of *B. pseudomallei* with typical resistance to aminoglycosides and susceptibility to ceftazidime, co-trimoxazole, and carbapenems. The isolate was further confirmed to be *B. pseudomallei* by the VITEK 2 automated system from our multispecialty tertiary care hospital laboratory with NABL and Joint Commission International accreditation.

## DISCUSSION

Melioidosis is an emerging tropical infection most commonly affecting adult men in particular geographic areas where contact with soil is present.<sup>[8]</sup> Diabetes is the most common risk factor for acquiring melioidosis as reported by many authors including authors from our city.<sup>[9]</sup> This could be the possible risk factor in our patient as he had a poor glycemic control and hailed from a city where previous reports of melioidosis were not uncommon. The presenting symptom in our patient was joint pain and swelling, consistent with septic arthritis. This sort of presentation has been reported from 18.75% of patients in a study from Chennai.<sup>[9]</sup> A recent study from Australia has suggested that 25.4% patients presented with septic arthritis suggesting that bone and joint involvement is becoming a common presentation of melioidosis.<sup>[10]</sup> Among joints, knee joints are the most commonly affected joints,



**Figure 1:** Dry, wrinkled colonies of *Burkholderia pseudomallei* on MacConkey agar

followed by ankle, hip, and shoulder joints. These patients also have elevated erythrocyte sedimentation rate, C-reactive protein, renal and liver functions similar to our patient.<sup>[10]</sup> The significance of this presentation was the rapidity of disease progression to septic shock, multiorgan failure, and death.

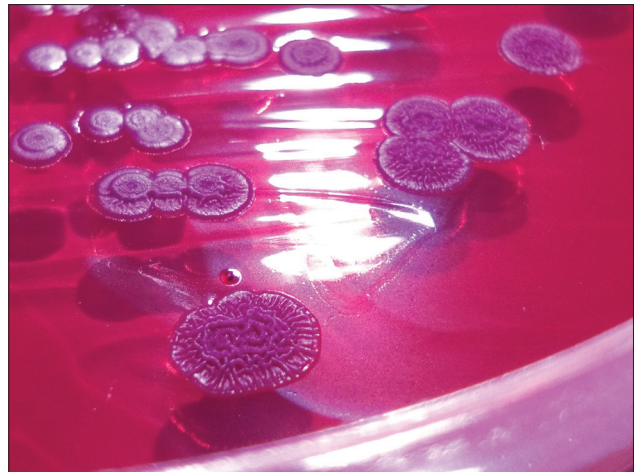
This organism is commonly reported as nonfermenting Gram-negative bacilli in resource-poor laboratories. It is important to identify this organism up to the species level due to various reasons: (1) *B. pseudomallei* is a community-acquired pathogen as compared to other *Pseudomonas* species which are hospital acquired. (2) It is susceptible to co-trimoxazole and doxycycline unlike majority of *Pseudomonas* species which are intrinsically resistant to co-trimoxazole.<sup>[11]</sup> (3) Co-trimoxazole and doxycycline are hence used for the treatment of melioidosis in the continuation phase of therapy.<sup>[10]</sup> (4) *B. pseudomallei* is intrinsically resistant to aminoglycosides and polymyxin B unlike other nonfermenting Gram-negative bacilli which are susceptible to these antibiotics.<sup>[12]</sup>

Treatment of melioidosis comprises two phases: acute phase (parenteral antibiotics given for  $\geq 10$  days) and eradication phase (oral antibiotics to complete a total of 20 weeks). Parenteral ceftazidime and carbapenems are used for the treatment of melioidosis in the acute phase of therapy. The superiority of using carbapenems is not very well established as treatment outcomes are almost similar with both these antibiotics.<sup>[13]</sup> However, a study from Australia demonstrated positive outcomes in patients treated with meropenem.<sup>[14]</sup> Meropenem showed lower MIC values in a case from Thailand when compared to imipenem, and a better treatment response was noted for the same. This makes meropenem a better choice of therapy compared to imipenem in treating melioidosis.<sup>[15]</sup> Meropenem is also known to lower the endotoxin release and is suggested to be a better choice of antibiotic for cases of severe sepsis when compared to ceftazidime and imipenem.<sup>[15]</sup> Eradication phase is mandatory due to the recalcitrant nature of melioidosis with its tendency to recur. A recent study conducted in Thailand (MERTH study) confirmed that the treatment of choice for the eradication phase of melioidosis treatment is oral co-trimoxazole monotherapy for a long duration.<sup>[13]</sup>

Isolation of the organism in culture remains the gold standard of diagnosis. Although isolation of the organism in selective media such as Ashdown's media is desirable, it is not always necessary as in our case where the organism was identified with its typical colony morphology from blood agar and MacConkey agar [Figure 2], confirmed by identification by Vitek 2 system. Specific antibiotics need to be included in the panel for testing due to its unusual pattern of susceptibility.

## CONCLUSION

In the recent past, due to a high number of case reports of melioidosis from India, it is wise to consider it in the initial differential diagnosis in patients presenting with bone and joint infections. Isolation of *B. pseudomallei* from blood or other clinical specimens is the gold standard of



**Figure 2:** The typical individual colony morphology of the organism

diagnosis. Early diagnosis is mandatory as this organism produces various virulence factors such as serine proteases and metalloproteases which are mainly responsible for degradation of collagen and fibronectin which results in dissemination of a localized infection, thereby causing sepsis. All these contribute to high mortality in patients, more so due to their immunosuppressed state. It is, therefore, necessary to create awareness among health-care professionals about the varied clinical manifestations which will aid them in early diagnosis and treatment to prevent fatal outcomes.

## Financial support and sponsorship

Nil.

## Conflicts of interest

There are no conflicts of interest.

## REFERENCES

- Morse SS. Factors in the emergence of infectious diseases. *Emerg Infect Dis* 1995;1:7-15.
- Cheng AC, Currie BJ. Melioidosis: Epidemiology, pathophysiology, and management. *Clin Microbiol Rev* 2005;18:383-416.
- Vidyalakshmi K, Shrikala B, Bharathi B, Suchitra U. Melioidosis: An under-diagnosed entity in Western coastal India: A clinico-microbiological analysis. *Indian J Med Microbiol* 2007;25:245-8.
- Roy PP, Agarwala A, Sarkar SK, Mandal A. PUO with multiple abscesses due to *Burkholderia pseudomallei*: A case report. *Int J Res Med Sci* 2015;3:2506-9.
- Pandey V, Rao SP, Rao S, Acharya KK, Chhabra SS. *Burkholderia pseudomallei* musculoskeletal infections (melioidosis) in India. *Indian J Orthop* 2010;44:216-20.
- Melikyan G, Badawi M, Akhtar N, Elsetouhy AH. Case of paraspinal collection due to *Burkholderia pseudomallei*. *BMJ Case Rep* 2013;2013. pii: Bcr2013201447.
- Limmathurotsakul D, Golding N, Dance DA, Messina JP, Pigott DM, Moyes CL, *et al.* Predicted global distribution of *Burkholderia pseudomallei* and burden of melioidosis. *Nat Microbiol* 2016;1:15008.
- Hassan MR, Pani SP, Peng NP, Voralu K, Vijayalakshmi N, Mehanderkar R, *et al.* Incidence, risk factors and clinical epidemiology of melioidosis: A complex socio-ecological emerging infectious disease in the Alor Setar region of Kedah, Malaysia. *BMC Infect Dis* 2010;10:302.
- Gopalakrishnan R, Sureshkumar D, Thirunarayan MA,

- Ramasubramanian V. Melioidosis: An emerging infection in India. *J Assoc Physicians India* 2013;61:612-4.
10. Shetty RP, Mathew M, Smith J, Morse LP, Mehta JA, Currie BJ. Management of melioidosis osteomyelitis and septic arthritis. *Bone Joint J* 2015;97-B:277-82.
  11. CLSI. Performance Standards for Antimicrobial Susceptibility Testing. CLSI Supplement M100S. 26<sup>th</sup> ed., Vol. 26. Wayne, PA: Clinical and Laboratory Standards Institute; 2016. p. 216.
  12. Mandell L, Bennett E, Dollin R. *Burkholderia pseudomallei* and *Burkholderia mallei*: Melioidosis and glanders. In: Krehling H, editor. Principles and Practice of Infectious Diseases. 7<sup>th</sup> ed. Churchill Livingstone: Elsevier publishers; 2010. p. 2869-78.
  13. Dance D. Treatment and prophylaxis of melioidosis. *Int J Antimicrob Agents* 2014;43:310-8.
  14. Cheng AC, Fisher DA, Anstey NM, Stephens DP, Jacups SP, Currie BJ. Outcomes of patients with melioidosis treated with meropenem. *Antimicrob Agents Chemother* 2004;48:1763-5.
  15. Laowansiri P, Shah S, Kiratisin P, Apisarnthanarak A. A role for carbapenem in the treatment of melioidosis in developing countries? *Int J Infect Dis* 2009;13:e331-2.