

Uncommon Presentation of an Unusual Foreign Body

Jayalaxmi S. Aihole, Pragalath Kumar¹

Departments of Paediatric Surgery and ¹Paediatric Medicine, Indira Gandhi Institute of Child Health, Bengaluru, Karnataka, India

Abstract

Esophageal foreign bodies (FBs) are common and can be the serious cause of morbidity and mortality in children. One-third of FBs, retained in the gastrointestinal tract, are found in the esophagus. Their management depends on the anatomical location, shape, size, and the duration of impaction. In children, unwitnessed esophageal FBs can present with respiratory symptoms such as stridor. Therefore, a high index of suspicion is generally required to avoid significant morbidity and mortality. We are reporting an unusual FB with unusual symptoms in a 2-year-old female child.

Keywords: Esophagus, foreign body, pharynx

INTRODUCTION

The aerodigestive foreign bodies (FBs) are most commonly seen among children of age 6 months–6 years.^[1-4] Impaction of FBs in the upper aerodigestive tract is a serious pathological condition and is particularly more common in children. The potentially fatal complications include mediastinitis, tracheoesophageal fistula, and retropharyngeal abscess, which can lead to septicemia, shock and hence require immediate treatment.^[4-7] Diagnosis at times becomes difficult because of the nonavailability of a clear history, lack of characteristic clinical features, and absence of characteristic radiological findings.^[6,7]

CASE REPORT

An apparently healthy 2-year-old female child brought to us with a history of noisy breathing, with no history of cold, cough, choking spell, or difficulty in swallowing or drooling of saliva, since morning. On examination, the child was irritable with audible stridor and no cyanosis. Her pulse rate was 112/min, respiratory rate of 48/min, blood pressure 84/60 mmHg, and SpO₂ of 76% on room air. On examination, trachea was central, suprasternal and sub costal retractions were present. On auscultation, the child had bilateral equal air entry with bilateral conducted sounds. Other systems were normal. Chest X-ray revealed prominent bronchovascular markings with no direct or indirect evidence of FB [Figure 1a].

In view of inspiratory stridor and child's worsening clinical parameters, suspicion of FB aspiration was raised. Hence, the child was subjected to rigid bronchoscopy, which revealed minimal purulent material in the trachea with no evidence of FB. However, child persisted to have respiratory symptoms post bronchoscopy and required ventilatory support for few days. We noticed drooling of saliva when the child was on ventilator; hence, computed tomography (CT) scan thorax was done which surprisingly revealed radiopaque linear FB posterior to cricopharynx [Figure 2a and b]. Flexible esophagoscopy revealed tear in the cricopharynx with metallic FB posterior to cricopharynx. The child was subjected to thoracoscopy at the same time, which revealed the sharp metallic FB, the metallic foil posterior to cricopharynx with tear in esophageal wall. Thoracoscopic removal of metallic sharp FB was done successfully [Figure 1b]. However, unfortunately, postoperatively, the patient could not be revived due to widespread sepsis.

DISCUSSION

FB ingestion is a commonly encountered problem in both children and adults, in emergency departments which requires

Address for correspondence: Dr. Jayalaxmi S Aihole,
Department of Paediatric Surgery, Indira Gandhi Institute of Child Health,
Bengaluru, Karnataka, India.
E-mail: jayalaxmisaihole@yahoo.com

Access this article online

Quick Response Code:



Website:
www.ijccm.org

DOI:
10.4103/ijccm.IJCCM_436_16

This is an open access article distributed under the terms of the Creative Commons Attribution-NonCommercial-ShareAlike 3.0 License, which allows others to remix, tweak, and build upon the work non-commercially, as long as the author is credited and the new creations are licensed under the identical terms.

For reprints contact: reprints@medknow.com

How to cite this article: Aihole JS, Kumar P. Uncommon presentation of an unusual foreign body. *Indian J Crit Care Med* 2017;21:460-2.

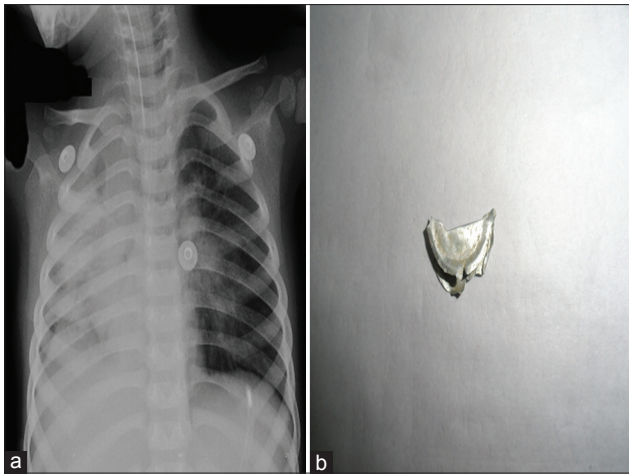


Figure 1: (a) Chest X-ray showing right lung consolidation with no evidence of radiopaque foreign body. (b) The foreign body, metallic foil retrieved by thoracoscopy

prompt diagnosis and management. The most common ingested FBs in children are coins, but meat bone, marbles, safety pins, hair clips, batteries, and screws are also been reported.^[3-5] Although most FBs in the digestive tract are passed spontaneously, 10%–20% of these patients need treatment, and approximately, 1% will require surgery. Literature also shows that incidence of impacted FBs is more among 2 years and older children.^[3-7] The common sites of impaction of FBs in esophagus are postcricoid region, level of aortic arch, left main bronchus, and diaphragm. Eighty percentage of impacted foreign objects are held up at cricopharynx. There is one more site of impaction, especially in cases of flat objects such as coin at the level of T1, i.e., thoracic inlet.^[7] Sharp FBs, if not retrieved at the earliest, may penetrate esophageal wall and can cause potentially serious complications.^[4]

Most common FBs in upper and mid esophagus are less likely to pass spontaneously; hence, immediate instrumentation are required for their retrieval.^[3-5,7]

The common signs and symptoms in a patient with a FB that has been retained for >24 hours tend to be gastrointestinal and include dysphasia, drooling, vomiting, gagging, and anorexia. Major respiratory symptoms are more common after weeks or months of ingestion such as coughing, stridor, fever, chest pain wheezing, chronic upper respiratory tract infections, pneumonia, and hemoptysis.^[4] Esophageal FBs can cause respiratory symptoms either by direct pressure on trachea, or indirectly by esophageal dilation and para esophageal edema compromising tracheal lumen, hence producing the symptoms.^[6,7]

Complications of retained esophageal FBs are primarily related to perforation of the esophagus which includes mediastinitis with or without abscess, esophagus to airway fistula, esophagus to vascular fistula, extraluminal migration of FB, and esophageal diverticula.^[5] Although the overall incidence of gastrointestinal perforation due to FB ingestion

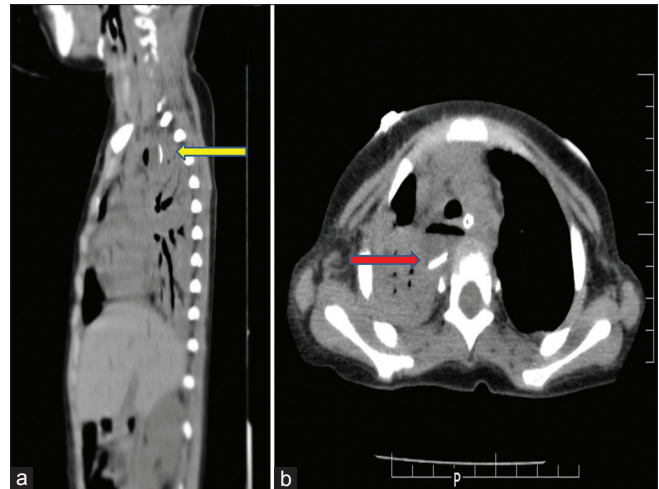


Figure 2: (a) Computed tomography scan thorax - sagittal section - radiopaque foreign body posterior to cricopharynx. (b) Computed tomography scan thorax - transverse section - radiopaque foreign body

is <1%, sharp and pointed objects result in perforation rates up to 35%.^[5] The mechanism by which these FBs migrate through the soft tissues is due to movement of neck muscles, esophageal peristalsis, carotid pulsations, tissue reaction as well as infection and abscess formation.^[6]

Posteroanterior, lateral cervical, and chest radiographs are basic radiological methods of FB detection. Since most FBs are radiolucent, the indirect findings such as laryngeal and tracheal deviation, hyper inflation with widening of inter costal spaces will raise the suspicion.

CT scanning of the neck and thorax is considered the most accurate imaging modality for diagnosing the presence of any FB impaction.^[4,5]

Many alternative methods for removal of FBs have been described in the literature such as dislodgment by a Foley catheter, advancement with bougie, papain or carbonated fluid treatment, glucagon therapy, and balloon extraction during fluoroscopy, but rigid endoscopy remains the gold standard treatment.^[5-7]

In this case report, learning points were; (1) Baby presented with respiratory distress and inspiratory stridor which made us to suspect airway FB initially, (2) The chest x ray did not show the presence of radio opaque metallic FB. Lateral x ray was not done, which might have helped us in the diagnosis and early intervention. (3) An early CECT of the chest and neck should be done whenever in doubt, which will aid in further management yielding favorable outcome.

Macpherson *et al.* stated that esophageal FBs can present with respiratory symptoms.^[7] Eisen *et al.* have stated that the thin object such as a razor blade can be difficult to visualize if it happens to be overlying the patient's spine at the time of imaging.^[2] Similarly, in our case, the sharp linear metallic FB, the metallic aluminium foil lying in and through crico pharynx was seen almost overlying the spine, hence was missed by

initial serial chest X-rays. However, when the FB migrated through the cricopharynx into the posterior mediastinum and in view of child's worsening clinical scenario, contrast-enhanced CT was done, which revealed the FB.

Only few cases of mortality related to complicated esophageal FBs have been reported in the literature.^[7]

CONCLUSION

Upper aero digestive tract FB in children can present with both esophageal and airway symptoms, hence a high index of suspicion is needed for prompt diagnosis and management. Two projections of chest X-ray imaging is preferred choice of investigation. When in doubt, CECT at the earliest will aid in accurate diagnosis and intervention.

Key points

- 1) Esophageal foreign body is a common problem that has the potential to cause significant local damage and can also compromise the breathing.
- 2) Respiratory symptoms are not always a sign of a primary problem in the respiratory system. Esophageal foreign body is a possibility that should be considered, which requires urgent surgical intervention.
- 3) Sharp objects have a tendency to get stuck at the level of the oropharynx or upper esophagus causing stridor. In these cases, direct vision or laryngoscopic-aided view could be enough to make the diagnosis and to extract the foreign body.
- 4) Sharp thin linear aluminum objects like metallic foil can be difficult to visualize by roentgenography, if they happen to be overlying the patient's spine at the time of imaging, hence can be missed.
- 5) A high index of suspicion must be maintained when the child presents to the emergency room with symptoms like stridor, dysphasia or drooling of saliva.

Financial support and sponsorship

Nil.

Conflicts of interest

There are no conflicts of interest.

REFERENCES

1. Chang MY, Chang ML, Wu CT. Esophageal perforation caused by fish vertebra ingestion in a seven-month-old infant demanded surgical intervention: A case report. *World J Gastroenterol* 2006;12:7213-5.
2. Eisen GM, Baron TH, Dominitz JA, Faigel DO, Goldstein JL, Johanson JF, *et al.* Guideline for the management of ingested foreign bodies. *Gastrointest Endosc* 2002;55:802-6.
3. Lee JH, Lee JS, Kim M J, Choe YH. Initial Location Determines Spontaneous Passage of foreign bodies from the Gastrointestinal Tract in Children. *Paediatr Emerg Care* 2011;27:284-89.
4. Shivakumar AM, Naik AS, Prashanth KB, Hongal GF, Chaturvedy G. Foreign bodies in upper digestive tract. *Indian J Otolaryngol Head Neck Surg* 2006;58:63-8.
5. Muhammad R, Khan Z, Jamil A, Malik S. Frequency of esophageal foreign bodies and their site of impaction in patients presenting with foreign body aerodigestive tract. *Eur Sci J* 2013;9:1857.
6. Sardana P, Bais AS, Singh VP, Arora M. Unusual foreign bodies of the aerodigestive tract. *Indian J Otolaryngol Head Neck Surg* 2002;54:123-6.
7. Macpherson RI, Hill JG, Othersen HB, Tagge EP, Smith CD. Esophageal foreign bodies in children: Diagnosis, treatment, and complications. *AJR Am J Roentgenol* 1996;166:919-24.