

Loss of Guidewire

Sir,

A male patient suffering from septic shock was referred to the university Intensive Care Unit from another hospital.

Here, a triple-lumen central venous catheter (CVC) was placed, through the right internal jugular vein, using the Seldinger technique. All three ports were aspirated and flushed. The inlying right subclavian CVC was removed. The entire procedure was described as unproblematic, and a bedside chest X-ray was ordered [Figure 1]. Unfortunately, this was misinterpreted.

As no source for the sepsis could be identified, a computed tomography scan was performed the next day. Surprisingly, hyperdense reflexes were observable in the right heart, most likely indicating a retained guidewire that had inadvertently not been pulled out during CVC placement [Figure 2]. Such

inattention-related incidences can result in a variety of potentially life-threatening cardiovascular morbidities.^[1] Accordingly, such lost guidewires should be removed as quickly as possible.

Interventional radiology is the recommended method.^[2] In this case, the guidewire was caught by a gooseneck snare, passed through the femoral vein using radiographic control, and was removed along with the vascular sheath [Figures 3 and 4].

Fortunately, the incidence of lost guidewires is rare; however, in one study, it was calculated to be 0.05%.^[3]

TAKE HOME MESSAGES

- Not losing guidewires is of the utmost importance
- While performing central venous access, always hold onto the wire
- If the wire does get lost, it is important to handle the incident appropriately (i.e., identification on chest X-ray and removal by means of interventional radiology).

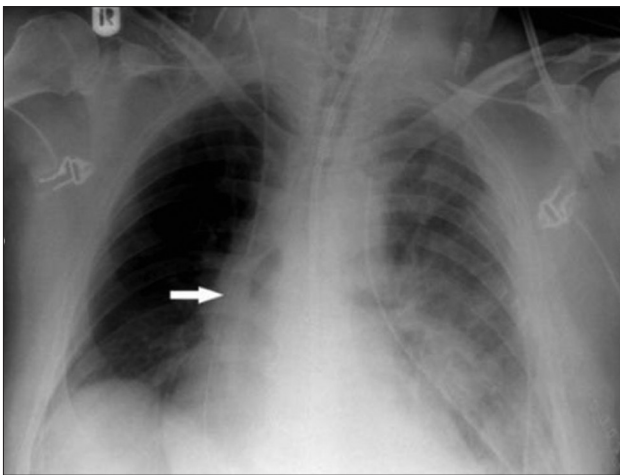


Figure 1: Guidewire (arrow) on bedside chest X-ray, below level of central venous catheter tip

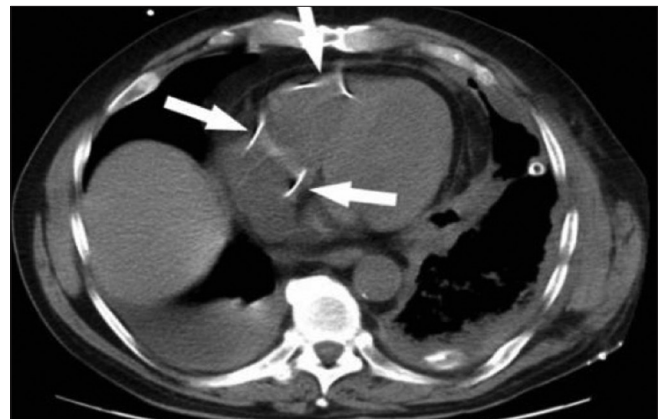

Figure 2: Guidewire in the right heart (arrows indicate reflexes of guidewire)

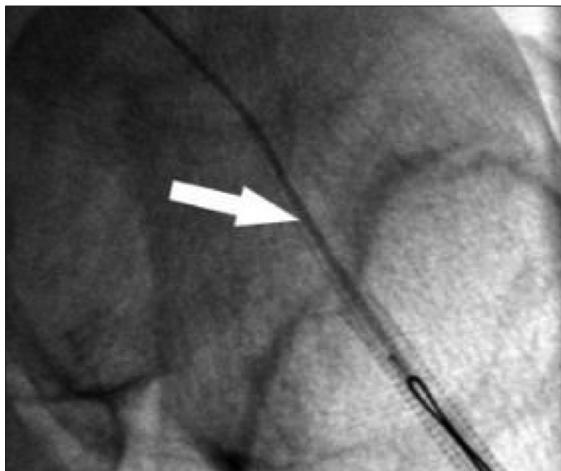


Figure 3: Aligning of guidewire (arrow)




Figure 4: Gooseneck snare with extracted guidewire

The patient's wife consented to publication of this letter.

Financial support and sponsorship

Nil.

Conflicts of interest

There are no conflicts of interest.

Wolfram Schummer^{1,2}

¹Friedrich Schiller University Jena, Jena, ²HELIOS Spital Überlingen, Überlingen, Germany

Address for correspondence: Dr. Wolfram Schummer, HELIOS Spital Überlingen, Härtenweg 2, 88662 Überlingen, Germany. Friedrich Schiller University Jena, Jena, Germany. E-mail: wolfram.schummer@web.de

REFERENCES

1. Schummer W, Schummer C, Gaser E, Bartunek R. Loss of the guide wire: Mishap or blunder? *Br J Anaesth* 2002;88:144-6.
2. Egglin TK, Dickey KW, Rosenblatt M, Pollak JS. Retrieval of intravascular foreign bodies: Experience in 32 cases. *AJR Am J*

Roentgenol 1995;164:1259-64.

3. Omar HR, Sprenker C, Karlnoski R, Mangar D, Miller J, Camporesi EM. The incidence of retained guidewires after central venous catheterization in a tertiary care center. *Am J Emerg Med* 2013;31:1528-30.

This is an open access journal, and articles are distributed under the terms of the Creative Commons Attribution-NonCommercial-ShareAlike 4.0 License, which allows others to remix, tweak, and build upon the work non-commercially, as long as appropriate credit is given and the new creations are licensed under the identical terms.

Access this article online	
Quick Response Code: 	Website: www.ijccm.org
	DOI: 10.4103/ijccm.IJCCM_93_18

How to cite this article: Schummer W. Loss of guidewire. *Indian J Crit Care Med* 2018;22:561-2.

© 2018 Indian Journal of Critical Care Medicine | Published by Wolters Kluwer - Medknow