

# Mechanisms of Hypoxia in COVID-19 Patients: A Pathophysiologic Reflection

Mohana Nitsure<sup>1</sup>, Bhakti Sarangi<sup>2</sup>, Guruprasad H Shankar<sup>3</sup>, Venkat S Reddy<sup>4</sup>, Ajay Walimbe<sup>5</sup>, Varsha Sharma<sup>6</sup>, Shirish Prayag<sup>7</sup>

## ABSTRACT

COVID-19 causes severe hypoxemia which fulfills the criteria of ARDS but is not accompanied by typical features of the syndrome. The combination of factors including low P/F ratios, high A-a gradient, relatively preserved lung mechanics, and normal pulmonary pressures may imply a process occurring on the vascular side of the alveolar–capillary unit. The scant but rapidly evolving data available on the pathophysiology are seemingly conflicting, indicating the relative dominance of intrapulmonary shunting or dead space in different studies. In this hypothesis paper, we attempt to gather and explain these observations within a unified conceptual framework by invoking the relative contributions of microvascular thrombosis, along with two proposed vascular mechanisms of capillary flow redistribution and flow through intrapulmonary arteriovenous anastomoses (IPAVA).

**Keywords:** Acute respiratory distress syndrome, COVID-19, Hypoxemia, Intra-pulmonary arteriovenous anastomoses.

*Indian Journal of Critical Care Medicine* (2020): 10.5005/jp-journals-10071-23547

Despite the circadian increase in the available literature on COVID-19, we are far from having a thorough understanding of its pathophysiology or established protocols for management. One of the more enigmatic unknowns for clinicians worldwide in the pathophysiology of COVID-19 is the mechanism/s by which it causes severe hypoxia with relatively preserved lung mechanics, especially in the early stages. The rapidly evolving data on the subject has prompted us to postulate a multifold pathophysiologic approach to these mechanism/s and their dynamic transition as well as overlap.

It is postulated that hypoxemia in COVID-19 is resultant of a V/Q mismatch due to a vascular pathology,<sup>1</sup> especially in the early stages. Loss of hypoxic pulmonary vasoregulation has been attributed as a mechanism in this scenario. As per Gattinoni et al.,<sup>2</sup> the lungs in the early phase (referred to as L Type/Type I) are characterized by low elastance, low recruitability, low ventilation to perfusion (V/Q) ratio, with computed tomography (CT) scan showing ground glass opacities only subpleurally and along fissures (presumably due to increased stress and strain in these areas from increased respiratory drive leading to high work of breathing). In this scenario, pulmonary artery pressures were found to be normal. In 16 patients, they showed respiratory system compliance of  $50.2 \pm 14.3$  mL/cm H<sub>2</sub>O associated with shunt fraction of  $0.50 \pm 0.11$ , a high shunt fraction/ to fraction of gasless tissue ( $3.0 \pm 2.1$ ).<sup>3</sup>

In contrast, Mauri et al.<sup>4</sup> demonstrated elevated ventilation–perfusion mismatch, with larger prevalence of ventilated nonperfused lung units (dead space) in comparison to perfused nonventilated units (shunt) with a dead space to shunt ratio of 2.3 ( $n = 7$ ).

We would like to hypothesize a theoretical model of the interplay of a various concepts in an attempt to explain these dilemmas.

The model involves the following components with a simultaneous spatial interaction and a temporal progression.

- Microvascular thrombosis is well documented to occur in COVID-19. The pulmonary microvascular thrombosis as demonstrated in autopsy studies<sup>5</sup> and reflecting in elevated D-Dimer levels<sup>6</sup> and the Chest CT as subsegmental vascular enlargement in vicinity

<sup>1–6</sup>Department of Pediatrics, Bharati Vidyapeeth Medical College and Hospital, Pune, Maharashtra, India

<sup>7</sup>Critical Care Medicine, Prayag Hospital, Shree Medical Foundation, Pune, Maharashtra, India

**Corresponding Author:** Guruprasad H Shankar, Department of Pediatrics, Bharati Vidyapeeth Medical College and Hospital, Pune, Maharashtra, India, Phone: +91 8971923275, e-mail: hsguru@gmail.com

**How to cite this article:** Nitsure M, Sarangi B, Shankar GH, Reddy VS, Walimbe A, Sharma V, et al. Mechanisms of Hypoxia in COVID-19 Patients: A Pathophysiologic Reflection. *Indian J Crit Care Med* 2020;24(10):967–970.

**Source of support:** Nil

**Conflict of interest:** None

of areas with ground glass opacities<sup>7</sup> has been consistently reported and associated with increased mortality. The elevated levels of markers such as D-Dimer, fibrinogen,<sup>8</sup> and interleukin 6<sup>7</sup> (IL-6) in published data are also supportive of a hypercoagulable state resulting from the underlying inflammatory process. Physiologically, the implication of this process in the context of the lung represents dead space with reduced/absent pulmonary capillary flow without affecting ventilation, thus leading to a high V/Q ratio. The same concept creates a window for the contemplation of therapeutic anticoagulation using low-molecular-weight heparin (LMWH)<sup>7</sup> in patients with increased D-Dimer, be it in the early phase of the disease.

- We hereby suggest two mechanisms of intrapulmonary vascular involvement, at the capillary as well as the precapillary level.
- The overt inflammatory process occurring in COVID-19 may be presumed to cause capillary hyperperfusion due to inducible nitric oxide synthase (iNOS) production, release of nitric oxide (NO), and local vasodilation. Both neutrophilic<sup>5,8</sup> and complement<sup>5</sup> activation, which have been demonstrated in COVID-19, may also lead to iNOS<sup>9–11</sup> expression. In early stages, inflammation is expected to occur in a nonuniform manner in the lungs, leading to uneven distribution of capillary perfusion

with a sprinkled alveolar scatter. This process leads to some alveolocapillary units with low V/Q ratios (normal/reduced ventilation but hyperperfused), henceforth referred to as Type A units and other units in which this pathology is not occurring in the early stages, what we here on refer to as Type B units. Hyperperfusion of the Type A units will lead to a circulatory steal of flow from Type B units, reducing their perfusion, while ventilation remains unchanged increasing the V/Q. The scatter of units with differing V/Q ratios in the same lung leads to mismatch and hypoxemia.

- Precapillary shunts are known to exist in lungs of healthy individuals termed intra-pulmonary arteriovenous anastomoses (IPAVA).<sup>12</sup> They are present in fetal life, and regress to some extent postnatally, and remain closed except in some circumstances as demonstrated in various studies (exercise, acute normobaric hypoxia, and  $\beta$ -adrenergic stimulation).<sup>13</sup> Although there are limited data on the physiological and pathophysiological roles of these vascular conduits, opening of these channels may well be hypothesized to occur with NOS expression, since such a mechanism has been shown in other causes of intrapulmonary shunting, like hepatopulmonary syndrome.<sup>14</sup> Also, opening of these channels may be considered in the prothrombotic adult population with COPD who are more prone to flow through the IPAVA.<sup>15</sup> These precapillary shunts cause hypoxemia by leading to decreased/absent capillary perfusion, again without compromising ventilation and have a high V/Q ratio. The presence of large diameter precapillary shunts in presence of a preexisting and/or superimposed hypercoagulable state may serve as an alternate pathway for thromboembolism and help explain the increased prevalence of cerebrovascular events described in various case series. Blood flow through these anastomoses is also inversely proportional to the fraction of inspired oxygen ( $\text{FiO}_2$ ),<sup>13</sup> thus leading to further contemplation of such patients requiring higher  $\text{FiO}_2$  to improve their oxygen saturation, despite no significant alveolar edema at this stage.

In both the abovementioned processes, since there is no alveolar hypoxia/diffusion abnormality, there may not be a trigger for hypoxic pulmonary vasoconstriction,<sup>16</sup> and pulmonary artery pressures in consequence may be normal as has been postulated by Gattinoni et al.<sup>2</sup>

All the abovementioned scenarios may lead to hypoxemia, low P/F ratios, and a high A-a gradient as seen in COVID-19 with fairly well-preserved lung compliance and may occur simultaneously in the earlier stages of the disease. They may cause dead space (microvascular thrombosis and precapillary shunt) or intrapulmonary shunt due to capillary flow redistribution. Hypoxemia thus induced will lead to increased respiratory drive through the stimulation of peripheral and central chemoreceptors, but the minute ventilation increase cannot improve the oxygenation since it would not affect vascular processes. The end result is a hypoxic–hypocapnic respiratory failure. The lungs will not be recruitable, as the compliance is already good, but proning may help oxygenation by improving the V/Q matching due to flow redistribution. The reversal of the proposed pathophysiology may vary depending on the extent and duration of inflammatory cascade, presence of contributing comorbidities, the treatment instituted, and secondary infection if any. Recent experiences have demonstrated a possible shifting paradigm in the management of these patients from early invasive mechanical ventilation to a trial with more gentle supports individualized based on ongoing physiological assessment<sup>17</sup>

through HFNC/NIV, early anti-inflammatory medications, and anticoagulation and is in tune with the proposed interplay of pathophysiologic mechanisms.

The findings in dual-energy CT imaging of the lung have also pointed to a possible role for previously underappreciated pulmonary vascular shunting in patients with COVID-19 as demonstrated by Lang et al.<sup>18</sup> recently. (Increased perfusion to areas of inflammation)

- As the illness progresses, features typical of the traditional ARDS are seen with low compliance, better recruitability, and high lung weight<sup>2</sup>—units that we would like to term Type C. Although the division of subtypes help with conceptual understanding, practically there will be overlap and eventual progression will occur with worsening parenchymal involvement. The Patient Self-Inflicted Lung Injury (P-SILI) occurring due to a combination of increasing negative intrathoracic pressure due to deep tidal breathing and increased lung permeability due to inflammation contribute to the development of Type C units causing interstitial lung edema.<sup>19</sup> Pulmonary hypertension may not be recorded in the early phases but can manifest when ARDS progresses. Type A and B alveoli eventually change to Type C and become the majority population with typical ARDS histology, physiology, imaging features, and pulmonary mechanics.

The coming together of all the abovementioned mechanisms and their temporal progression has been represented in the Tables 1 and 2 and Figure 1.

**Table 1:** Proposed chronologic progression in early stage COVID 19

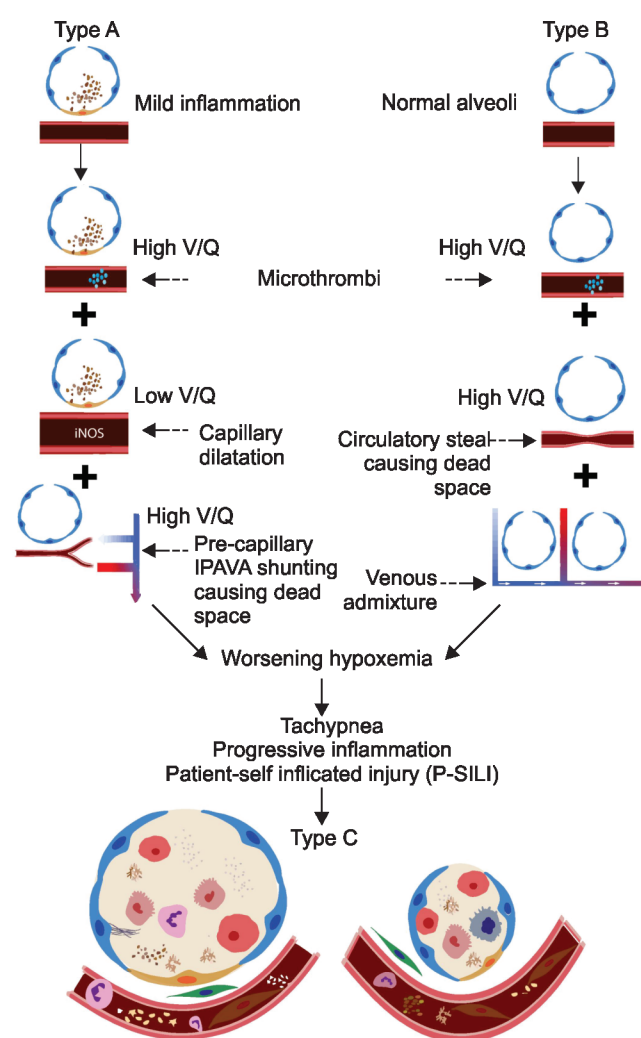
Type A alveoli (L Type)	Type B alveoli
Mildly inflamed (early stage)	Normal
Good compliance and low elastance	Same
Microthrombi start forming in capillaries and arterioles and increasing leading to dead space locally (increasing V/Q)	Microthrombi in capillaries/arterioles may be present in these units also.
Vascular obstruction leads to more flow redistribution to Type B alveoli	Low V/Q, venous admixture
iNOS—capillary dilation and/or precapillary shunting—IPAVA	Normal vessels, IPAVA
Hypoxic vaso-constriction is lost	Not relevant
Venous admixture begins to increase	Circulatory steal begins from Type A alveoli
Low V/Q ratios locally (capillary dilation), High ratio if IPAVA	High V/Q ratios due to circulatory steal (dead space)
Contribute to global hypoxia in a big way	Also contribute
Clinically increasing dyspnoea, tachypnea, P-SILI	Same
Low V/Q ratios in Type A and high V/Q ratios in Type B both contribute to global hypoxia in the initial phases	
Management—HFNC or NIV, early intubation (less preferable), gentle ventilation with low PEEP as dictated by the compliance, deep sedation, paralysis/ anti-inflammatory medications, anticoagulation	

V/Q, ventilation/perfusion; IPAVA, intrapulmonary arteriovenous anastomosis; iNOS, inducible nitric oxide synthase; NO, nitric oxide; HFNC, high flow nasal cannula; NIV, noninvasive ventilation; ARDS, acute respiratory distress syndrome; P-SILI, patient self inflicted lung injury

**Table 2:** Chronology of late phase alveolar events

<i>Type C alveoli (H Type)</i>
Increasing inflammation, alveoli, interstitium and vessels are all involved
Gradual worsening of compliance and ARDS pathology progresses
Type A and B alveoli get converted to Type C with low V/Q ratios over time
Hypoxia due to venous admixture, shunting from alveolar involvement, added to dead space caused by worsening microthrombi.
Further increase in dyspnoea, tachypnoea, P-SILI
CO <sub>2</sub> rises in contrast to earlier stage, pulmonary hypertension which is not present earlier may become apparent as features of typical ARDS progress.
Management—mechanical ventilation with typical ARDS protocols including prone positioning, organ support

V/Q, ventilation/perfusion; ARDS, acute respiratory distress syndrome; P-SILI, patient self-inflicted lung injury



**Fig. 1:** Proposed chronology of events in COVID-19. V/Q, ventilation/perfusion; IPAVA, intrapulmonary arteriovenous anastomosis; iNOS, inducible nitric oxide synthase; ARDS, acute respiratory distress syndrome; P-SILI, patient self inflicted lung injury

The above discussed pathophysiologic approach is based on the available literature, and our understanding of pulmonary physiology and attempts to unify the stands taken by different groups when explaining extremes of the mechanisms of hypoxia caused by COVID-19 with a dynamic representation of events occurring simultaneously and over time. We anticipate the rigors of expert scrutiny and encourage further studies. All said and done, the slightest contribution to better patient outcomes through these deliberations, if at all, would be a satisfactory outcome indeed.

## REFERENCES

- Marini JJ, Gattinoni L. Management of COVID-19 respiratory distress. JAMA 2020. DOI: 10.1001/jama.2020.6825.
- Gattinoni L, Chiumello D, Caironi P, Busana M, Romitti F, Brazzi L, et al. COVID-19 pneumonia: different respiratory treatments for different phenotypes? Intensive Care Med 2020;46(6):1099–1102. DOI: 10.1007/s00134-020-06033-2.
- Gattinoni L, Coppola S, Cressoni M, Busana M, Rossi S, Chiumello D. COVID-19 does not lead to a “typical” acute respiratory distress syndrome. Am J Respir Crit Care Med 2020;202(4):618–619. DOI: 10.1164/rccm.202004-1106LE.
- Mauri T, Spinelli E, Scotti E, Colussi G, Basile MC, Crotti S, et al. Potential for lung recruitment and ventilation-perfusion mismatch in patients with the acute respiratory distress syndrome from coronavirus disease 2019. Crit Care Med 2020. DOI: 10.1097/CCM.0000000000004386.
- Magro C, Mulvey JJ, Berlin D, Nuovo G, Salvatore S, Harp J, et al. Complement associated microvascular injury and thrombosis in the pathogenesis of severe COVID-19 infection: a report of five cases. Transl Res 2020;220:1–13. DOI: 10.1016/j.trsl.2020.04.007.
- Wang D, Hu B, Hu C, Zhu F, Liu X, Zhang J, et al. Clinical characteristics of 138 hospitalized patients with 2019 novel coronavirus-infected pneumonia in Wuhan, china. JAMA 2020;323(11):1061–1069. DOI: 10.1001/jama.2020.1585.
- Oudkerk M, Büller HR, Kuijpers D, van Es N, Oudkerk SF, McCloud TC, et al. Diagnosis, prevention, and treatment of thromboembolic complications in COVID-19: report of the national institute for public health of the Netherlands. Radiology 2020. 201629. DOI: 10.1148/radiol.2020201629.
- Ranucci M, Ballotta A, Di Dedda U, Bayshnikova E, Dei Poli M, Resta M, et al. The procoagulant pattern of patients with COVID-19 acute respiratory distress syndrome. J Thromb Haemost 2020;18(7):1747–1751. DOI: 10.1111/jth.14854.
- Lagunas-Rangel FA. Neutrophil-to-lymphocyte ratio and lymphocyte-to-C-reactive protein ratio in patients with severe coronavirus disease 2019 (COVID-19): a meta-analysis. J Med Virol 2020. DOI: 10.1002/jmv.25819.
- Jacob A, Hensley LK, Safratowich BD, Quigg RJ, Alexander JJ. The role of the complement cascade in endotoxin-induced septic encephalopathy. Lab Invest 2007;87(12):1186–1194. DOI: 10.1038/labinvest.3700686.
- Kröncke KD, Fehsel K, Kolb-Bachofen V. Inducible nitric oxide synthase in human diseases. Clin Exp Immunol 1998;113(2):147. DOI: 10.1046/j.1365-2249.1998.00648.x.
- Lovering AT, Duke JW, Elliott JE. Intrapulmonary arteriovenous anastomoses in humans—response to exercise and the environment. J Physiol 2015;593(3):507–520. DOI: 10.1113/jphysiol.2014.275495.
- Lovering AT, Riemer RK, Thébaud B. Intrapulmonary arteriovenous anastomoses. Physiological, pathophysiological, or both. Ann Am Thorac Soc 2013;10(5):504–508. DOI: 10.1513/AnnalsATS.201308-265ED.
- Vettukattil JJ. Pathogenesis of pulmonary arteriovenous malformations:role of hepatopulmonary interactions. Heart 2002;88(6):561–563. DOI: 10.1136/heart.88.6.561.
- Norris HC, Mangum TS, Kern JP, Elliott JE, Beasley KM, Goodman RD, et al. Intrapulmonary arteriovenous anastomoses in humans with chronic obstructive pulmonary disease: implications for

- cryptogenic stroke? *Exp Physiol* 2016;101(8):1128–1142. DOI: 10.1113/EP085811.
16. Dunham-Snary KJ, Wu D, Sykes EA, Thakrar A, Parlow LR, Mewburn JD, et al. Hypoxic pulmonary vasoconstriction: from molecular mechanisms to medicine. *Chest* 2017;151(1):181–192. DOI: 10.1016/j.chest.2016.09.001.
17. Tobin MJ. Basing respiratory management of coronavirus on physiological principles. *Am J Respir Crit Care Med* 2020;201(11):1319–1320. DOI: 10.1164/rccm.202004-1076ED.
18. Lang M, Som A, Mendoza DP, Flores EJ, Reid N, Carey D, et al. Hypoxaemia related to COVID-19: vascular and perfusion abnormalities on dual-energy CT. *Lancet Infect Dis* 2020.
19. Brochard L, Slutsky A, Pesenti A. Mechanical ventilation to minimize progression of lung injury in acute respiratory failure. *Am J Respir Crit Care Med* 2017;195(4):438–442. DOI: 10.1164/rccm.201605-1081CP.