

Procedures in COVID-19 Patients: Part-II

Rajesh K Pande¹, Ashish Bhalla², Sheila N Myatra³, Lakshmi N Yaddanpuddi⁴, Sachin Gupta⁵, Tapas K Sahoo⁶, Ravi Prakash⁷, Tarun A Sahu⁸, Akansha Jain⁹, Palepu BN Gopal¹⁰, Dhruva Chaudhry¹¹, Deepak Govil¹², Subhal Dixit¹³, Srinivas Samavedam¹⁴

ABSTRACT

Critical care in the era of novel coronavirus disease-2019 (COVID-19) infection has multiple challenges including management of the patient, underlying comorbidities, and the complications. With no end in sight to the pandemic, intensive care unit (ICU) practitioners and hospital administrators have to join hands to prepare for the long battle ahead. Critically ill COVID-19 patients need imaging or image-guided interventions in one form or the other including X-rays, ultrasonography (USG), echocardiography (ECHO), and CT scan. These patients often require renal replacement therapy (RRT) for either the preexisting chronic renal insufficiency or acutely developing kidney injury. Another important component of care is transfer of the patient to and fro from the ICU or to higher care centers. Most of the ICUs are equipped with modern facilities but with increasing number of patients a large number of makeshift arrangements are being made for managing these patients. This position paper outlines important tips to formulate protocols and procedures for critically ill patients, who are managed in the ICU.

Keywords: Acute kidney injury, Airway, Ambulance, Continuous renal replacement therapy, COVID-19, CT scan, Hemodialysis, SARS-CoV-2, Ultrasonography interventional.

Indian Journal of Critical Care Medicine (2020): 10.5005/jp-journals-10071-23604

IMAGING IN COVID AREAS (INTENSIVE CARE UNIT/WARDS)

Radiological imaging is the backbone of management in critical care units and intensive care units (ICUs) and provides essential information regarding the structural integrity and functioning of lung parenchyma and heart.^{1,2} Besides providing a window to lung parenchymal pathology in coronavirus disease-2019 (COVID-19) cases, it provides important information regarding progression of disease, complications related to ventilation, and any other coexisting underlying pathological conditions.³

Although chest radiograph is less sensitive in providing the extent of parenchymal involvement in critically ill COVID-19 patient/suspects, but the ease of performing, portability, low radiation exposure, and ease of disinfection makes it an important investigation choice in critical care units.^{3,4}

The thoracic radiography can be supplemented by point-of-care ultrasound (POCUS) to provide information about the structural as well as functional integrity of lung.⁵ POCUS is, however, operator dependent and a minimal proficiency is essential before it can be recommended as a care tool.⁵ POCUS can help in evaluation of cardiac structure and function, assessment of abdominal organ, heart, and vessels in relation to shock, venous system for deep venous thrombosis (DVT), and intracranial pressure measurement making it a very effective tool in critically ill patients.⁶ POCUS also obviates the need for auscultation and acts like a "visual stethoscope" preventing infection exposure to COVID-19 in healthcare worker (HCW).^{5,6} It can also help in evaluating airway, confirming tube placement, evaluating vessels, and assisting for intra-arterial/venous catheter placement. In addition, POCUS can also assist in performing bedside interventions in critically ill patients.

The key aims of these guidelines are to provide diagnostic and interventional support to COVID-19 patients and to achieve sufficient capacity for managing these patients in ICUs. The guidelines emphasize on bedside radiological investigation/interventions, timing them in COVID patient cohorts, avoiding

^{1,7}Department of Critical Care Medicine, BLK Center for Critical Care, BLK Superspecialty Hospital, New Delhi, India

²Department of Internal Medicine, Postgraduate Institute of Medical Education and Research, Chandigarh, India

^{3,8}Department of Anaesthesiology, Critical Care and Pain, Tata Memorial Hospital, Homi Bhabha National Institute, Mumbai, Maharashtra, India

⁴Department of Anaesthesiology and Critical Care, Postgraduate Institute of Medical Education and Research, Chandigarh, India

⁵Department of Critical Care, Narayana Superspecialty Hospital, Gurugram, Haryana, India

⁶Department of Critical Care Medicine, Institute of Critical Care, Medanta Hospital, Ranchi, Jharkhand, India

⁹Department of Paediatric ICU, Bhagwan Mahavir Medical Superspecialty Hospital, Ranchi, Jharkhand, India

¹⁰Department of Critical Care, Continental Hospital, Hyderabad, Telangana, India

¹¹Department of Pulmonary and Critical Care, Pandit Bhagwat Dayal Sharma Post Graduate Institute of Medical Sciences, Rohtak, Haryana, India

¹²Department of Critical Care Medicine, Institute of Critical Care and Anesthesia, Medanta: The Medicity, Gurugram, Haryana, India

¹³Department of Critical Care Medicine, Sanjeevan and MJM Hospital, Pune, Maharashtra, India

¹⁴Department of Critical Care, Virinchi Hospital, Hyderabad, Telangana, India

Corresponding Author: Ashish Bhalla, Department of Internal Medicine, Postgraduate Institute of Medical Education and Research, Chandigarh, India, Phone: +91 9417023973, e-mail: bhalla.chd@gmail.com

How to cite this article: Pande RK, Bhalla A, Myatra SN, Yaddanpuddi LN, Gupta S, Sahoo TK, *et al.* Procedures in COVID-19 Patients: Part-II. *Indian J Crit Care Med* 2020;24(Suppl 5):S272-S279.

Source of support: Nil

Conflict of interest: None

unnecessary patient transport to the radiology department. There is no need for routine imaging/daily imaging of all patients, and imaging decisions should be based on clinical status of the patient.

If possible, dedicated portable X-ray and sonography machines should be stationed permanently in COVID areas (ward/ICU).

The radiology teams can be rostered on a weekly rotation basis to provide service to COVID areas if possible. All the staff involved in radiological procedures must be adequately trained in donning and doffing of personal protective equipments (PPEs) as well as disinfection and cleaning of the machines. If possible, they should be trained to manage minor technical difficulties with the machines before starting their rotations. For most imaging procedures, PPE consists of an impermeable gown, gloves, eye protection (goggles/face shields), and a mask (standard/contact/droplet). A triple-layer surgical mask with face shield would be adequate in most settings (ventilated patients); however, in ICU areas where noninvasive ventilation (NIV), high flow nasal cannula (HFNC), and nebulization are being used and the risk of aerosol generation is high, HCW should wear N95 respirator mask. The disinfection and cleaning can be done after the last positive patient has been investigated in COVID areas (ward/ICU).

It is difficult to formulate evidence-based recommendations for radiological procedures in critically ill COVID-19 patients (suspect or positive), since there is very limited literature available. We have also adopted/modified the guidelines for performing radiological procedures in COVID-19 patients given by Department of Health and Family Welfare, Kerala, in writing this position paper.⁷ Some of the suggestions are listed below:

Requesting a Radiological Examination

The resident/staff in the critical care unit/ICU can raise a digital request through Hospital Information Software (HIS) for radiological investigations on the advice of the consultant. In the absence of HIS, a telephonic request should be made to avoid any physical exchange of papers from COVID areas.

Standard Operating Procedures for Performing Radiological Procedures

General Instructions

- No medically emergent radiological procedure should be denied.
- It is necessary to delay nonurgent procedures until the crisis period is over.
- Radiological emergency procedures are to be decided carefully after proper communication between the radiologists and referring physician.
- Radiologist should be divided into teams as this will prevent disabling of entire intervention radiology (IR) team, should quarantine be required.
- The portable X-ray and ultrasound machine should be dedicated for use in COVID areas (ward/ICU) and should not be used in non-COVID areas.
- If radiological interventions cannot be performed bedside and patient needs to be transferred to IR room, preplanned green corridors should be used minimizing the risks of infections en route.
- All necessary aerosol-generating precautions must be taken for the patient, and staff involved in radiological procedures.
- Decontamination of the portable X-ray and ultrasound machines should be done after use as per the hospital protocol.

- All surfaces of the portable equipment should preferably be duly covered to avoid possible contamination. In between patients, the ultrasonography (USG) probes should be decontaminated as per the infection control protocol.
- Disposable linen should preferably be used for covering the patient, equipment, and surfaces. Clean and contaminated work areas are to be clearly demarcated to contain contaminated objects and subjects, thereby facilitating subsequent clean up.
- During the procedure, frequent changes of probes/touching of uncovered surface should be avoided.
- If possible, the patient should be covered with a plastic sheet.
- After the sonography, appropriate disinfectant compatible with the machine should be used to disinfect the machine.⁸
- If possible, recording of the procedure should be made for subsequent review by the consultant radiologist.

Instructions for Patient's Room

- Radiologist and radiology staff should enter COVID areas after donning PPEs as per the protocol. The radiographer should put on the radio protective lead apron over PPE.⁹
- Patient details should be rechecked, infectious risk identified, and ensure that the patient is masked.⁹
- Ensure that no aerosol-generating procedure is being carried out.
- If the patient is awake and cooperative, inform about the radiological procedure, and give necessary verbal instructions for body positioning. If patient is sedated, give such instructions to the nursing staff.
- Suspected or confirmed awake patients should wear a surgical face mask in COVID areas.
- Care must be taken if the patient is on high-flow nasal oxygen or NIV as there is likely to be aerosol generation and N95 respirator mask should also be used along with PPE by the radiologist.⁹
- Ensure that there should be enough space for maneuvering the machine.

Instructions for Patients and Referring Physician

- Emergency IR cases should be given priority, over routine, and elective cases.
- Instructions given to facilitate the IR procedure to the ICU staff should be verified, before the start of procedure.
- Consents should be taken before any intervention. Telephonic consent should be documented in the file and signed by the treating surgeon/physician.
- In case the patient and family are unable to give consent for an emergency procedure, the indications and need for procedure should be documented and verified by two separate physicians/surgeons involved in care.
- Take time out to identify the patient, procedure to be performed, and check the informed consent. All pre-procedural instructions, equipment should be checked before the intervention outside the intervention room/anteroom.

Instructions for Staffs

- Sanitize hands alcohol-based sanitizer frequently.
- Gloved hands should be sanitized after touching the machine/equipments around the patient in ICU.
- Radiologist should do surgical scrubbing before radiological intervention.
- Radiology staff should don PPE as prescribed and maintain sterility.

Specific Procedures

X-ray

- Maintain a separate logbook for portable X-ray machine's downtime.
- One-hour downtime is essential for decontamination of portable machine and passive air exchange depending on the agent used.
- Coordinate with clinical team to arrange time for routine X-ray.
- Club X-ray requests from a unit/area together and do X-ray at a fixed time to minimize the duration of exposure.
- Insert patient details and place X-ray detector in plastic sleeve before proceeding to patient's room. Multiple X-rays should preferably be done in one designated room/area.
- For non-digital portable X-ray machine, radiographer should keep all the X-ray plates' ready, wrapped in plastic sleeves.
- Place the detector in correct position behind the patient, with minimal contact with patient and surroundings.
- Sanitize gloved hands and center the intensifier.
- Sanitize gloved hands and expose. Ensure adequacy of image on monitor.
- Take X-ray detector from behind the patient and place sleeved detector on floor.
- Sanitize gloved hands, remove detector from sleeve, and place in portable machine.
- Discard the sleeve and sanitize gloved hands.
- Bring portable machine outside patient area. Clean and disinfect the machine and the detector with alcohol-based sanitizer and alcohol-based wet wipes (70% ethanol or isopropyl alcohol).⁸
- Place the machine at designated spot for further use.
- Perform doffing as per the institute guidelines.
- The findings on chest radiograph should be labeled as one of the following:¹⁰
 - Typical: The common pattern seen consists of lower lobe and peripheral predominant, multiple, bilateral areas of consolidation.
 - Indeterminate: The radiograph does not fit the typical/atypical descriptors.
 - Atypical: Radiographs with uncommon/unreported features, such as pneumothorax, lobar pneumonia, pleural effusion, or pulmonary edema.
 - Negative: A normal chest with no abnormal finding does not exclude the possibility of COVID-19.

Ultrasonography and Interventional Radiological Procedures

- USG-guided interventions should be performed at the bedside or preferably in a designated area in the COVID ICU/ward.
- Under appropriate circumstances, physical barriers like plastic/ acrylic boxes or plastic sheets/covers may be placed to limit interpersonal contact while performing USG.
- Patient details including the indications, limitations, and plan of POCUS should be properly documented and discussed with referring physician before starting the POCUS.⁶
- The characteristic findings seen in lung ultrasound include:¹¹
 - Thickened pleural line with irregularity, focal/multifocal/ confluent B lines, and patterns of consolidation are commonly seen in the posterior lower lung fields.
 - Appearance of A lines during recovery.

- Reduced blood supply on Doppler.
- Pleural effusions are relatively uncommon.

Post-POCUS/Intervention Clean-up

- Use proper doffing and disposal of PPE as per the hospital recommendations. Biohazard material disposal policy of the hospital should be followed.
- Access reporting workstations to review and write reports only after doffing.
- Ensure decontamination of ultrasound machine and place it at designated spot for further use.

Computed Tomography Scan

- CT scan should not be used as a screening or diagnostic tool for COVID-19.¹² CT scan of the chest should not be the basis for quarantine of a patient in the absence of a positive real time polymerase chain reaction (RT-PCR).
- There is a wide variation in the reported sensitivities (60–98%) and specificities (25–53%) of CT scans in COVID-19 patients.
- CT scans should be reserved for hospitalized, symptomatic patients who have specific clinical indications, such as organizing pneumonia vs acute respiratory distress syndrome (ARDS).
- Prior appointment should be fixed after consultation with the radiologist. It is appropriate to schedule CT scan of COVID patients at the end of the day, as the CT suite has to be disinfected after use before scanning subsequent patients. The downtime should not affect the regular services of the department.
- The radiologists should familiarize with the CT appearance of COVID-19 infection in order to be able to identify findings consistent with infection in patients imaged for other reasons.
- A normal chest CT does not mean a person does not have COVID-19 infection and an abnormal CT is not specific for COVID-19 diagnosis.
- CT scan report in suspected and proven COVID-19 patients must conclude the findings as:¹³
 - Typical: These include commonly seen findings that are bilateral peripheral ground-glass opacities (GGOs) with or without consolidation, rounded morphology or visible interlobular lines.
 - Indeterminate: There is an absence of typical imaging features with non-specific less commonly identified imaging features, like GGOs with non-rounded morphology, and lack of specific distribution.
 - Atypical: There is a lack of typical and indeterminate features with uncommon/unreported imaging features, like cavitation, and small nodules.
 - Negative for pneumonia: No CT features suggestive of pneumonia.
- The differential diagnosis of the imaging findings of COVID-19 include *Pneumocystis carinii* pneumonia, cryptogenic organizing pneumonia, drug toxicities, other viral pneumonias, fungal pneumonia and alveolar hemorrhage.
- CT suite and waiting area should be decontaminated.
- Exposed surfaces including door handles, arm guards, TV monitors, console panels in the console room, and keyboards are to be wiped with 70% ethanol or chlorhexidine–ethanol wipes.⁹
- Floors should be mopped with environment protection agency (EPA)-registered hospital grade disinfectant and rooms should be ventilated for at least 30 minutes before bringing in next patient.

RENAL REPLACEMENT THERAPY IN COVID-19

Introduction

The incidence of acute kidney injury (AKI) in COVID infection is around 25%. The presence of AKI is associated with increased mortality, more so when RRT is required.¹⁴ Till date, no specific treatment for COVID-19-induced AKI has been established. The treatment revolves around providing RRT to these patients based on the knowledge gained in non-COVID patients. There is no evidence supporting the efficacy of one modality of RRT over another, and RRT should be offered on patient's clinical requirement. The timing, dose, and modality (continuous or intermittent) of RRT remain same as for non-COVID patients.¹⁵ Ministry of Health and Family Welfare has issued some guidelines in this regard.¹⁶

General Precautions

- Patients coming for routine hemodialysis session should have an earmarked space in the hospital. If possible, a separate area/room may be identified for such patients.
- Hospital should fix the time slots for dialysis in COVID-positive patients, preferable the last slot of the day that will provide adequate time for disinfection of the machines and premises.
- COVID-19 patient scheduled for dialysis should be cohorted in the same area at the same time.
- The dialysis room should be sanitized after the session using standard disinfection practices.
- All patients should wear N95 mask while they are undergoing dialysis in the hospital.
- Dedicated hemodialysis machine/s should be demarcated for COVID-19-positive patients.
- For admitted patients with AKI requiring hemodialysis, it should be preferably done in their isolation room or in ICU. The ICU should have reverse osmosis (RO) water pipeline to facilitate hemodialysis. Transport for dialysis should be minimized.
- In case interhospital/intrahospital transport for dialysis is needed, COVID precautions and transport protocols should be followed. Proper precautions should be taken as per the transport guidelines.

Measures to be Taken by Dialysis Staff

- The dialysis staff should be screened for comorbidities and symptoms every day.
- The staff without any risk factors/comorbidities should be preferred for the management of COVID-19 patients.
- The technicians/staff performing the dialysis session should wear appropriate PPE to prevent contact as well as aerosol transmission.
- If possible, the patient should be monitored from outside the room through a glass window or a monitor.
- Avoid 1:1 nurse patient ratio for hemodialysis session, so that the exposure to the staff decreases.
- All dialysis sessions should preferably be done in negative pressure rooms. If there is shortage of such rooms, then the COVID-19 dialysis area should be separate from non-COVID dialysis patients.
- If there are no hepatitis B patients undergoing dialysis sessions, then the end stage renal disease (ESRD) patients can undergo dialysis in the hepatitis B isolation room or any such earmarked room.
- All disposable medical supplies should be discarded as per the prescribed infection control practice policies of the institute.

- All patients undergoing dialysis should be stationed at least 6 feet apart from each other during their sessions.

Mode of Dialysis

- There is no literature available about preference of one mode of RRT over another.
- Hemodynamically unstable patients in multi-organ failure should undergo continuous renal replacement therapy (CRRT) due to better hemodynamic control.¹⁷
- As CRRT is mostly done by ICU staff, the exposure to the dialysis staff may decrease.
- Using long extension tubing, the CRRT machine can be stationed outside the isolation room, so that the staff need not enter the patient's room. However, the disadvantage of such long tubing's is that the patient may become hypothermic due to long extracorporeal circuit.¹⁸
- The effluent from CRRT should be discarded as per the standard hospital protocols.
- The use of extracorporeal therapies like cytosorb and oxiris is still experimental in nature and has not been recommended for COVID-19.¹⁹
- As COVID is a hypercoagulable state, the use of unfractionated heparin during intermittent hemodialysis should be done. For CRRT, regional citrate anticoagulation may be used to prevent filter blockage.

Dialysis Machine Disinfection

- The dialysis machine should be disinfected as per the standard protocols. The surface cleaning of the machines should be done by any hospital grade disinfectant (preferably 70% ethanol wet wipes) in order to prevent cross contamination of other surfaces or equipment.
- The CRRT machine should undergo surface cleaning as per the routine protocol. A hospital grade disinfectant like 1% sodium hypochlorite should be used to clean the CRRT machine body.
- For touch screens of the machines, the manufacturer's guidelines should be followed.
- The machine should preferably be covered with a disposable plastic sheet to prevent contamination. These sheets can be disposed as per the hospital policies.
- All other surfaces or unused machines, monitors, stands, and trolleys should also undergo surface cleaning after each session of dialysis to reduce fomite spread.

To reduce the burden of AKI-related complications in COVID patients, early initiation of RRT along with the use of experimental extracorporeal therapies should be evaluated. The guidelines proposed by various scientific societies should be looked to formulate the local policy for the hospital.²⁰⁻²²

Dialysis of Patient with Acute Kidney Injury in Intensive Care Unit¹⁶

Around 5% of patients with COVID-19 infections admitted in ICU may have new onset AKI or worsening of their preexisting chronic kidney failure. The acute kidney insult may vary from mild to severe and a number of patients may require RRT in ICU. A significant proportion of patients may end up developing secondary bacterial infection, many will progress to septic shock. Drug/contrast-induced

nephrotoxicity may result in AKI or result in worsening of existing chronic kidney disease (CKD) needing RRT.

We suggested that decision to use RRT in patients with AKI should depend on their clinical status. Patient admitted in critical care units/ICUs should be preferably given bedside dialysis rather than shifting patient in main dialysis unit. If piped RO water supply is not available in COVID areas, RO water in a tank will serve the purpose for dialysis. The provision for portable RO water unit and portable dialysis machine, with appropriate water inlet pressure and adequate drainage in case of a leak, must be available in the ICU.

If more dialysis is expected in COVID areas (ICU/wards), a dedicated dialysis machine may be stationed there for dialysis, as this will help in preventing contamination and risk of infection due frequent shifting of dialysis machines and patients.

Peritoneal Dialysis¹⁶

Peritoneal dialysis (PD) is not a preferred modality in critically ill patients due to infection, preexisting comorbidities, and poor perfusion due to shock. However, it may be needed if the patients are on continuous ambulatory peritoneal dialysis (CAPD). It offers these patients a relative advantage of not being exposed to hospital-acquired multidrug-resistant bugs, unlike patients who are receiving hospital- or satellite-based hemodialysis treatment. Adequate supply of dialysis fluid should be available/ensured to avoid missing dialysis exchanges.

Used dialysis bags and tubing are potentially infective and should be properly disposed using 1% hypochlorite solution first and disposed in a sealed bag. Used dialysis fluid should be properly drained in the common drains.

In patients where hemodialysis (HD) may not be possible due to certain reasons, PD may be the last resort.

Properly trained HCW should insert PD catheter and dialysis should be properly supervised. Healthcare worker should use all precautions while initiating acute PD and discard used consumables properly, according to the institutional policies.

TRANSPORT OF COVID-19 PATIENTS

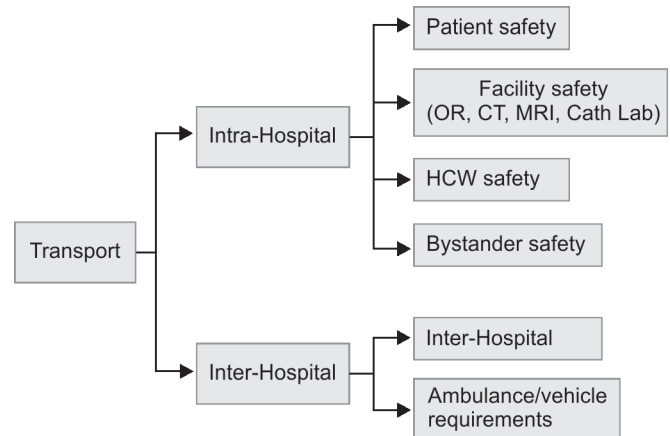
Introduction

Patients with suspected COVID-19 can infect other people at any time, including during transfer and transport. The virus has a high human-to-human transmissibility via airborne, droplet, and contact routes.^{23,24} Like other patients, COVID patients may also require intrahospital or interhospital transfer for various reasons. Intrahospital transfer may be required from emergency department to the ICUs, operation theaters, radiology suites, and isolation wards. Interhospital transfer may be required from smaller hospitals to bigger centers for ICU care, ventilation, dialysis, and COVID treatment including plasma therapy.

Interhospital transfer may also be necessitated when patient needs specialized therapies like ECMO, which are not locally available. Potential breach in infection control practices can occur, while transporting patient outside the COVID areas. The management becomes exceptionally challenging, when patient's condition deteriorates during transport, as the accompanying staff would be wearing cumbersome PPE.²⁴

Transport can be intrahospital or interhospital which is discussed under the major subheadings as highlighted in Flowchart 1.

Flowchart 1: Safety and process measures in transport of COVID-19 patients



Intrahospital Transport

Specific Measures

Healthcare worker involved in transport of COVID-19 patients should be familiar with the need for early transfer of deteriorating patients to ICU, bystander safety, post-transport decontamination, and should have a preplanned contingency plan for medical emergencies during transport.²⁵⁻²⁷

Patient Safety

- Low threshold to intubate prior to transport if needed.
- Continuous monitoring of vitals along with ETCO₂ in intubated patients.
- Avoid hand bagging. Use transport ventilator for intrahospital transfer, with best parameter settings based on clinical parameters and pre-transport arterial blood gas (ABG) values. In case only hand ventilation is available, use a bacteria-virus or high efficiency particulate air (HEPA) filter between the endotracheal tube (ETT) and the circuit.
- Accompanying critical care physician should be the transport team leader, responsible for the airway.
- Check position of ETT at lip before starting to identify displacement during transport.
- The transport team leader should be at the head end of the patient, so that he/she can watch for any displacement of lines, catheters, or ETT, and issue directions to the team to stop if the need arises.
- Pre-transport brief should be discussed with the transport team to ensure preparedness (emergency drugs, extra equipments, disposal bags) and contingency plans for possible complications and challenges.
- Patient and team movement should be well coordinated, and if, there is any incoordination, the team leader should loudly ask the team to readjust.
- Ensure battery back-up for monitor and infusion pump and transport ventilator.
- A backup team comprising of ICU physician and nurse should be immediately available if required.

Healthcare Worker Safety

- All transport staff should be mask-fitted for N95 respirators.
- Don full PPE prior to transport.

- Put a surgical mask covering patient's nose and mouth during transport.
- Avoid using open breathing circuits, or high-flow nasal oxygenation and noninvasive positive-pressure ventilator with a vented mask during transport.
- Apply HEPA filter at the expiratory end of the ventilator circuit, or between the ETT and the resuscitator bag if bagging is required.
- Avoid unnecessary breathing circuit disconnections during transport.
- Apply transparent drape to cover the patient (such that enables easy access to the airway).
- Apply transparent protective covers for equipments.
- CT scans and magnetic resonance imaging (MRI) should be performed at the end of the day if possible, to allow for terminal cleaning of CT/MRI suite.
- Names of transport team members should be mentioned on their PPE's to avoid confusion.
- Ensure closed loop communication among team members.
- Use sign language in addition to speech for communication as hearing is quite challenging after donning PPE.
- Allocates equipment and staff (e.g., drivers, HCWs).
- Prepares for transfer—Stabilizes patient before starting, communicate about patient's condition with receiving hospital and estimated time of arrival, designates trained staff to accompany patient.
- Ensures using triple-layered mask and gloves for patient and attendant.
- Uses a designated route as much as possible and feasible.
- Monitors the patient's condition and provides necessary care.
- Takes airborne precautions (including fit-tested and fit-checked N95 particulate respirators for staff) when aerosol-generating procedures are performed.
- Provides coordinated handover of the patient in the triage area.
- Maintains a transfer log and a copy of each patient's medical records.
- Optimizes ventilation in vehicles during transport (open windows if possible, to reduce risk of transmission of infectious droplets).
- Monitors and documents the health of all staff involved in transfer and transport, including activities performed during contact with patients.
- Staff to doff PPE at destination after transport.
- Staff to don new PPE for the return journey prior to retuning in the same ambulance.
- Staff to doff PPE in the nearest clinical area, for example, ambulance bay, upon arrival.
- Undertakes terminal cleaning of ambulance upon arrival when back at primary hospital.

Bystander Safety

- Green corridor—A preplanned dedicated transport route should be available for each destination. Transition zone should be clearly delineated and separated from other clean zones and checkpoints. These routes are not to be taken by hospital staff working in non-COVID areas.
- Transport should be planned at a specific time of the day (preferably after regular hours).
- Personnel preparation: The team should include porter, security staff, and the transport team.
- Security team should ensure clearance of the bystanders along the designated route well before the start of transport process.

Rescue and Contingency Plans during Transport

- The need for intubation should be assessed prior to transport. Intubation is best done in ICU under controlled settings.
- Prepare transport equipment and drugs in anticipation of medical emergencies, such as sudden cardiovascular collapse or hypotension.
- Gentle bagging by bag valve mask (BVM) fitted with heat and moisture exchanger (HME) filter to reduce aerosolization in the event of worsening hypoxemia or ventilator malfunction or loss of power.

Process Flow^{28,29}

The transport process flow is described in a tabular form (Table 1).

Interhospital Transport^{28,29}

The interhospital transport requires preparation between wide groups of teams. Pre-transport checklist and timeout should be followed for every transport.

Composition of Transport Team

There should be a coordinating body (a common point of contact between different teams). Broadly there are two teams: Healthcare provider and transport teams. Transport team includes physician, nurse, technician, and the driver.

Transport Team

- Responds to the coordinating body for arranging safe transfer of patients.

Ambulance/Vehicle Requirements²⁹

- Sealed separation between the driver's cabin and the patient compartment in the back. If the vehicle design does not allow such, make sure all windows are open for ventilation.
- Furnished with a stretcher, PPE, essential equipment, cleaning agent and disinfectant, alcohol-based hand rub, and has a specialized area for contaminated goods including a bin with a secure lid (keep only the essential equipment and materials required for immediate use).
- Equipped with communication equipment, such as mobile phone, SMS system, and satellite phone.
- Clean and disinfect the patient compartment part of the vehicle after each use.
- Turn off air conditioning or electric ventilation with enclosed vents and built in filters, to prevent possible aerosolized particles from circulating in the air vents that may remain there, when air becomes static after being turned off.
- Team members should maintain adequate physical distance inside ambulance.
- Transportation routes: Plan transportation route in advance to minimize the amount of contact with other personnel (i.e., utilize service elevators, direct routes as much as possible).

Common for Intrahospital and Interhospital Transport^{28,29}

- Clean and disinfect the vehicle/area/route/elevator and equipment after each transfer (1% sodium hypochlorite solution). Replenish supplies and dispose of waste as per the infection control guidelines.

Table 1: Process flow in transport of COVID-19 patients

Ward/ER to ICU referral	Handover between consultants over phone. Details: <ul style="list-style-type: none"> • Weight of patient. • Chief complaints and issues. • Intubated vs non-intubated (ventilator setting—TV, frequency, I:E ratio, FIO₂, PEEP, mode, compliance). • Airway difficulty (encountered or expected), ETT size, and depth inserted (cm. mark at lip). • Hemodynamic status and inotrope support (number of infusion pumps in use). • Any known allergies.
Preparation in ICU	Perform pre-transport checklist and timeout. Non-intubated—No changes in bed space. Intubated— <ul style="list-style-type: none"> • Remove unnecessary equipments (e.g., self-inflating bag). • Keep ventilator ready with mode and settings in standby. • Ventilator circuit to have in-line suction. • HME filter should be present between the patient and the ETCO₂. • HEPA or BVF should be present between ventilator and the expiratory limb of ventilator circuit. Prepare to intubate <ul style="list-style-type: none"> • Keep intubation trolley with ETT as appropriate, LMA, emergency front of neck (EFONA) equipments, suction catheter, laryngoscope/glidoscope, intubation box, tapes, 2 mL syringe, RSI drugs, emergency drugs. • Keep <i>infusion pump stand</i> ready. • Monitor with chest leads and SpO₂ probe to be kept ready and switched on.
Prepare to leave ER/ward	<ul style="list-style-type: none"> • ER/ward team leader to contact ICU nurse-in-change to confirm designated bed space, inform current clinical status of patient, and discuss any additional requirements anticipated for the patient. • ER team: 1 Dr, 1 nurse, 1 technician all in PPE. • All required imaging to be done prior to shifting. • Team leader (TL) to allocate roles and discuss plan for possible complications and do pre-brief before starting transport. • Patient should be connected to transport ventilator. • If patient is on O₂ by nasal prong, put a surgical mask covering mouth and nose. • Paperwork to be put in plastic bag. • COVID corridor cleared and security alerted to keep the COVID lift ready. • ICU doctor, nurse, and technician to be ready in full PPE to receive the patient.
Arrival to ICU and handover	<p>Following in order as per the team preference:</p> <ul style="list-style-type: none"> • Patient moved to ICU bed. • Ventilator changeover: <ul style="list-style-type: none"> • Set FIO₂ to 1.0 in ICU ventilator and attach the ventilator circuit with HEPA or BVF at the expiratory end. • Put transport ventilator on standby mode. Clamp the ETT and disconnect of nonpatient side of HME and connect to the ICU ventilator circuit. • Unclamp ETT and start ventilation. Check for chest movements and ETCO₂ waveform if available. • Change from transport to ICU monitor. No loss of monitoring should occur during this process. • Handover should be done. • Negative pressure room must be closed prior to ventilator changeover. • All reusable equipments like transport ventilator, infusion pumps, monitor should be decontaminated by wiping with 1% hypochlorite solution. • ER/ward team follow doffing procedure.

- Clean and disinfect reusable patient-care equipment with alcohol-based hand rub before using on another patient.
- Maintain sufficient supplies of PPE, staff training, and support personnel like security officers and cleaning crews.
- Follow infection control practices including hand hygiene, PPE, special precaution for aerosol-generating procedure, and decontamination.
- Use of pre-transport checklist, timeout, and simulation exercises is some of the best and safest means of preparation as they allow

performing the task without risking patient, helps in checking gaps in system, and fills them and hence preparing one to face challenges.³⁰

Critically ill COVID-19 patients will require a number of life-saving investigations and interventions like imaging RRT. Some of these investigations and interventions will require interhospital or intrahospital shifting, and appropriate care for preventing infections in the patients and HCW during procedures/transport is very important. Formulating protocols and standard operating procedures for procedures and transportation will not only increase safety but also help the clinicians deal with critically ill COVID-19 patients in a better and confident manner.

REFERENCES

1. Trotman-Dickenson B. Radiology in the intensive care unit (part 1). *J Intensive Care Med* 2003;18(4):198–210. DOI: 10.1177/0885066603251897.
2. Trotman-Dickenson B. Radiology in the intensive care unit (part 2). *J Intensive Care Med* 2003;18(5):239–252. DOI: 10.1177/0885066603254087.
3. Vancheri SG, Savietto G, Ballati F, Maggi A, Canino C, Bortolotto C, et al. Radiographic findings in 240 patients with COVID-19 pneumonia: time-dependence after the onset of symptoms. *Eur Radiol* 2020. 1–9. DOI: 10.1007/s00330-020-06967-7.
4. ACR (2020) ACR recommendations for the use of chest radiography and computed tomography (CT) for suspected COVID-19 infection. American College of Radiology, Virginia Available via <https://www.acr.org/Advocacy-and-Economics/ACR-Position-Statements/Recommendations-for-Chest-Radiography-and-CT-for-Suspected-COVID19-Infection>. Accessed 26 Mar 2020.
5. Mitchell C, Rahko PS, Blauwet LA, Canaday B, Finstuen JA, Foster MC, et al. Guidelines for performing a comprehensive transthoracic echocardiographic examination in adults: recommendations from the American Society of Echocardiography. *J Am Soc Echocardiogr* 2019;32(1):1–64. DOI: 10.1016/j.echo.2018.06.004.
6. Johri AM, Galen B, Kirkpatrick JN, Lanspa M, Mulvagh S, Thamman R. ASE statement on point-of-care ultrasound during the 2019 novel coronavirus pandemic. *J Am Soc Echocardiogr* 2020;33(6):670–673. DOI: 10.1016/j.echo.2020.04.017.
7. Covid standard operating procedure for radiological procedures. Formulated by Department of radiodiagnosis and imaging, Sri Chitra Institute. Approved by Covid cell, SCTIMST. 31/3/2020.
8. Mossa-Basha M, Medverd J, Linnau K, Lynch JB, Wener MH, Kicska G, et al. Policies and guidelines for COVID-19 preparedness: experiences from the University of Washington. *Radiology* 2020. 201326. DOI: 10.1148/radiol.2020201326.
9. How to sanitize portable X-ray equipment. <https://www.elearning.isrrt.org/mod/book/tool/print/index.php?id=310&chapterid=142>.
10. Rodriguez-Morales AJ, Cardona-Ospina JA, Gutiérrez-Ocampo E, Villamizar-Peña R, Holguin-Rivera Y, Escalera-Antezana JP, et al. Clinical, laboratory and imaging features of COVID-19: a systematic review and meta-analysis. *Travel Med Infect Dis* 2020;34:101623. DOI: 10.1016/j.tmaid.2020.101623.
11. Ahuja A, Mahajan A. Imaging and COVID-19: preparing the radiologist for the pandemic. *Cancer Res Stat Treat* 2020;3(Suppl S1):80–85. DOI: 10.4103/CRST.CRST_134_20.
12. ACR Recommendations for the use of Chest Radiography and Computed Tomography (CT) for Suspected COVID-19 Infection. Available from: <https://www.acr.org/Advocacy-and-Economics/ACR-Position-Statements/Recommendations-for-Chest-Radiography-and-CT-for-Suspected-COVID19-Infection>. [Last accessed on 2020 Apr 12].
13. Simpson S, Kay FU, Abbara S, Bhalla S, Chung JH, Chung M, et al. Radiological Society of North America Expert consensus statement on reporting chest CT findings related to COVID-19. Endorsed by the Society of Thoracic Radiology, the American College of Radiology, and RSNA – secondary publication. *Radiology* 2020;35(4):219–227. DOI: 10.1097/rti.0000000000000524.
14. Naicker S, Yang CW, Hwang SJ, Liu BC, Chen JH, Jha V. The novel coronavirus 2019 epidemic and kidneys. *Kidney Int* 2020;97(5):824–828. DOI: 10.1016/j.kint.2020.03.001.
15. Gaudry S, Hajage D, Schortgen F, Martin-Lefevre L, Pons B, Boulet E, et al. Initiation strategies for renal-replacement therapy in the intensive care unit. *N Engl J Med* 2016;375(2):122–133. DOI: 10.1056/NEJMoa1603017.
16. <https://www.mohfw.gov.in/pdf/GuidelinesforDialysisofCovid19Patients.pdf>.
17. Yang Yi, Shi Jia, Shuwang GE, Shjiming G, Xue X, Yanan W, et al. Effect of continuous renal replacement therapy on all-cause mortality in COVID-19 patients undergoing invasive mechanical ventilation: a retrospective cohort study. 2020. DOI: 10.1101/2020.03.16.20036780.
18. Anna Burgner T, Ikizler ALP, Dwyer JP. COVID-19 and the inpatient dialysis unit. *CJASN* 2020;15(5):720–722. DOI: 10.2215/CJN.03750320.
19. Ronco C, Reis T. Kidney involvement in COVID-19 and rationale for extracorporeal therapies. *Nat Rev Nephrol* 2020;16(6):308–310. DOI: 10.1038/s41581-020-0284-7.
20. Expert Team of Chinese Medical Association Nephrology Branch. Recommendations for prevention and control of novel coronavirus infection in blood purification center (room) from the Chinese Medical Association Nephrology Branch[J]. *Chin J Nephrol* 2020;36(2):82–84. DOI: 10.3760/cma.j.issn.1001-7097.2020.02.002.
21. Hwang SJ. Guideline for dialysis facilities during COVID-19 outbreak. *Taiwan Soc Nephrol* 2020.
22. American Society of Nephrology. Information for Screening and Management of COVID-19 in the Outpatient Dialysis Facility. February 28, 2020 <https://www.cdc.gov/coronavirus/2019-ncov/index.html>; accessed 11 March 2020.
23. CDC. Updated protocol on airborne precautions, 2020, <https://www.cdc.gov/coronavirus/2019-ncov/hcp/clinical-guidance-management-patients.html>.
24. Li Q, Guan X, Wu P, Wang X, Zhou L, Tong Y, et al. Early transmission dynamics in Wuhan, China, of novel coronavirus-infected pneumonia. *N Engl J Med* 2020;382(13):1199–1207. DOI: 10.1056/NEJMoa2001316.
25. Wax RS, Christian MD. Practical recommendations for critical care and anaesthesiology teams caring for novel coronavirus (2019-nCoV) patients. *Can J Anesth* 2020;67(5):568–576. DOI: 10.1007/s12630-020-01591-x.
26. Liew MF, Siow WT, Yau YW, See KC. Safe patient transport for COVID-19. *Crit Care* 2020;24(1):94. DOI: 10.1186/s13054-020-2828-4.
27. Pan L, Wang L, Huang X. How to face the novel coronavirus infection during the 2019-2020 epidemic: the experience of sichuan provincial people's hospital. *Intensive Care Med* 2020;46(4):573–575. DOI: 10.1007/s00134-020-05964-0.
28. WHO. Infection prevention during transfer and transport of patients with suspected COVID-19 requiring hospital care. Interim guidance March 27, 2020.
29. Ministry of Health and Family Welfare Directorate General of Health Services [Emergency Medical Relief]. Coronavirus Disease 2019 (COVID-19): Standard Operating Procedure (SOP) for transporting a suspect/confirmed case of COVID-19.
30. Deepak R, Rakshay S. Role of simulation in COVID-19 management. *J Pediatr Crit Care* 2020;7(7):S72–S75. DOI: 10.4103/JPCC.JPCC_65_20.