

Tocilizumab—An Effective Therapy for Severely and Critically Ill COVID-19 Patients

Sudhir Bhandari¹, Govind Rankawat², Ajeet Singh³

ABSTRACT

Background: Tocilizumab (TCZ), a monoclonal antibody against the most prevalent cytokine interleukin-6 (IL-6), is an emerging therapeutic option for COVID-19 infections. The present study was undertaken to assess the therapeutic response of TCZ therapy in severely or critically ill COVID-19 patients and its role as an effective modality of management.

Methods: The present retrospective observational study included 30 admitted severely or critically ill COVID-19 patients, treated with TCZ therapy on behalf of raised IL-6 levels. The patient's data concerning medical history, clinical manifestation, arterial blood gas analysis, mode of oxygenation, radiological imaging, and outcome were extracted from their medical records and compared pre- and post-TCZ infusion.

Results: All patients of the study group had symptomatic presentations with a mean PaO₂/FiO₂ (PF) ratio of 205.41 before TCZ infusion. All patients had a raised IL-6 level (mean value 206.56 pg/mL) that was extremely elevated in 90% of patients. Infusion of TCZ dramatically reduced mean body temperature (100.78–99.32°F) and the requirement for supplemental oxygen (68–48%) and improved mean SpO₂ (86–89%) and mean PF ratio (208–240) within 24 hours. Three patients on noninvasive ventilation were weaned off after TCZ infusion. Serum levels of IL-6 were raised initially but declined within 3 to 5 days of post-TCZ infusion.

Conclusion: TCZ appears to be an effective therapeutic option in severely or critically ill COVID-19 patients with raised IL-6 levels. TCZ immediately improves the clinical status of patients by a probable mechanism of inhibition of cytokine storm and reduces COVID-19-related mortalities.

Keywords: COVID-19, Cytokine storm, Interleukin-6, Tocilizumab.

Indian Journal of Critical Care Medicine (2021): 10.5005/jp-journals-10071-23747

INTRODUCTION

A novel severe acute respiratory syndrome coronavirus-2 (SARS-CoV-2), the COVID-19 pathogen, is responsible for protean clinical manifestations ranging from asymptomatic to severe pneumonia and acute lung failure.¹ Coronavirus has an average incubation period of 5 to 6 days. The most common clinical manifestations of COVID-19-positive patients include fever, cough, shortness of breath, fatigue, loss of appetite, sputum production, joint pain, nausea, vomiting, and diarrhea. The complications of COVID-19 include pneumonia, acute respiratory distress syndrome (ARDS), multiorgan failure, septic shock, disseminated intravascular coagulation, and death.^{2,3}

The pathogenesis of SARS-CoV-2 is initiated by viral–host cell interaction through binding of spike protein to host receptors via receptor-binding domains of angiotensin-converting enzyme 2 (ACE2).⁴ A large number of T-lymphocytes and mononuclear macrophages are subsequently activated producing cytokines, such as interleukin-6 (IL-6), that bind to the IL-6 receptor on the target cells, initiating cytokine storm and severe inflammatory responses in the lungs and other tissues. IL-6 receptor (IL-6R) has two forms: membrane-bound interleukin-6 receptor (mIL-6R) and soluble interleukin-6 receptor (sIL-6R). IL-6 binds to sIL-6R to form a complex, which then binds to glycoprotein 130 on the cell membrane to complete trans-signal transduction and play a proinflammatory role.^{5–7} IL-6 is the most common cytokine reported in SARS-CoV-2 infection and has been implicated in inducing various clinical manifestations, radiological features, management modalities, and outcomes. Therefore, early identification, treatment, and prevention of a cytokine storm are essential for such patients.

^{1–3}Department of General Medicine, SMS Medical College and Hospital, Jaipur, Rajasthan, India

Corresponding Author: Govind Rankawat, Department of General Medicine, SMS Medical College and Hospital, Jaipur, Rajasthan, India, Phone: +91 08290523606, e-mail: govindrakawat@gmail.com

How to cite this article: Rankawat G, Bhandari S, Singh A. Tocilizumab—An Effective Therapy for Severely and Critically Ill COVID-19 Patients. *Indian J Crit Care Med* 2021;25(3):260–266.

Source of support: Nil

Conflict of interest: None

Tocilizumab (TCZ), a humanized monoclonal antibody against IL-6R, has been recommended in seriously ill patients with an elevated IL-6.⁸ However, there are limited data relating to the safety and efficacy of TCZ on the inflammatory overdrive activity in such severe COVID-19 patients, and subsequently the present study was designed to assess the treatment response of TCZ, an IL-6R antagonist, in severely and critically ill COVID-19 patients and the efficacy of TCZ to provide a therapeutic strategy for this disease of global concern.

METHODS

Study Design

The present retrospective observational study was conducted on 30 severely or critically ill COVID-19-positive patients, admitted to S.M.S. Medical College and Attached Hospitals, Jaipur, India till June 25, 2020. This study was approved by the institutional ethics

committee of the institution. In the present study, RT-PCR-positive patients for SARS-CoV-2 were included with a raised serum level of IL-6 and were treated with a single dose of TCZ (8 mg/kg or 400 mg given slowly in 100 mL normal saline over 1 hour). Severely or critically ill patients who were included for TCZ infusion were serially observed and the data were collected accordingly.

Data Collection

COVID-19 was diagnosed based upon World Health Organization interim guidance.¹ Patient information regarding demographic data, medical history, clinical manifestations, general physical examination, laboratory findings, blood gas analysis, chest radiograph findings, high-resolution computed tomography (HRCT) scans of the chest of available patients, and oxygen support at presentation were extracted from medical records for data analysis. Laboratory investigations included hemoglobin levels, total leukocyte count (TLC), platelet count, and IL-6, blood gas analysis through oxygen saturation at room air (SpO₂), partial pressure of oxygen in arterial blood (PaO₂), PF (PaO₂/FiO₂) ratio, and supplemental oxygen (FiO₂) required to maintain SpO₂ >95%. Severely or critically ill patients were included in this study as per Indian Council of Medical Research (ICMR) guidelines. Severely ill category patients were COVID-19 positive with clinical signs of pneumonia (fever, cough, shortness of breath, and fast breathing), respiratory distress, and SpO₂ >90% on room air. Critically ill category COVID-19-positive patients had clinical signs of severe pneumonia and radiological evidence of bilateral opacities in the chest with respiratory failure and COVID-19-related complications like ARDS, sepsis, septic shock, etc., after exclusion of other causes. Required oxygen support tool for maintenance included a low-flow mask (nasal prongs, oxygen mask, etc.), high-flow mask, noninvasive ventilation (NIV), and invasive ventilation. HRCT chest was evaluated to categorize CT severity score (*assigned of 25 based on the percentage of area involved in each of the five lobes*).⁹ All patients were serially followed for their clinical status, blood gas analysis (especially SpO₂, PaO₂, and PF ratio), requirement of FiO₂ to maintain SpO₂ >95%, tools for FiO₂ therapy, and a serum level of IL-6 before and after TCZ infusion. Data were documented serially before the transfusion of TCZ therapy (day 0) followed by postinfusion of TCZ therapy on days 1, 3, 5, and 7. Data concerning the outcome of lives, duration of seroconversion (time taken from first positive RT-PCR to first negative RT-PCR for COVID-19), and duration of hospital stays were also collected. Patients who had incomplete medical records were excluded from the study. The data were compiled, tabulated, interpreted, and correlated to assess the efficacy of TCZ in severely or critically ill COVID-19 patients.

Statistical Analysis

Quantitative data were expressed as mean and standard deviation. Qualitative data were expressed as proportions. Follow-up data were correlated with paired *t*-test and the level of significance was assigned for a *p*-value less than 0.05. Statistical package for the social sciences) and R-program were used for statistical analysis.

RESULTS

A total of 30 COVID-19 patients were included in the present study. The mean age of SARS-CoV-2-infected patients treated with TCZ was 49.6 years (49.6 ± 10.55). A male preponderance was observed with 63.33% males and 36.37% females (Table 1).

Table 1: Characteristics of COVID-19 patients at presentation before transfusion of tocilizumab (TCZ)

Characteristics	Patients (N = 30)
Age (Year)	49.6 ± 10.55
Gender	
Male	19 (63.33%)
Female	11 (36.67%)
Clinical manifestations	
Cough	27 (90%)
Shortness of breath	27 (90%)
Fever	23 (76.76%)
Temperature (°F)	100.78 ± 1.74
<98.6°F	7 (23.33%)
98.6–100°F	2 (6.67%)
>100°F	21 (70%)
Other symptoms	10 (33.33%)
Chronic medical illnesses	14 (46.67%)
Diabetes mellitus	10 (33.33%)
Hypertension	6 (20.00%)
Coronary artery disease	2 (6.67%)
Pulmonary disease	1 (3.33%)
Blood gas analysis	
SpO₂ at room air (29/30)	86.24% ± 4.1
<85%	10 (34.48%)
85–90%	16 (55.17%)
>90%	3 (10.34%)
PF ratio (PaO₂/FiO₂)	205.41 ± 46.68
<150	4 (13.33%)
150–250	18 (60.00%)
>250	8 (26.27%)
Supplemental oxygen	59.93% ± 19.57
<40%	6 (20.00%)
40–60%	13 (43.33%)
>60%	11 (36.67%)
Disease severity	
Severely ill	24 (80.00%)
Critically ill	6 (20.00%)
Laboratory investigations	
Hemoglobin	13.60 ± 0.80
Total leukocyte count	7.27 ± 2.52
Platelet	2.40 ± 0.78
Interleukin-6 (IL-6)	206.56 ± 142.72
Elevated (up to 10 times of upper limits of normal [ULN])	3 (10.00%)
Extremely elevated (>10 times of ULN)	27 (90.00%)
CT severity score (12/30)	16.16 ± 3.99
<15	4 (33.33%)
15–20	6 (50.00%)
>20	2 (16.67%)
Oxygen support	
Low-flow mask	6 (20.00%)
High-flow mask	18 (60.00%)
Noninvasive ventilation	5 (16.67%)
Invasive ventilator	1 (3.33%)
Outcome	
Alive	28 (93.33%)
Death	2 (6.67%)
Average duration of seroconversion	10.08 ± 4.06
Average duration of hospital stay	12.25 ± 4.95

Before TCZ Transfusion (Day 0) (Table 1)

All patients had COVID-19-related clinical symptoms at their presentation that included cough in 27 patients (90%), shortness of breath in 27 patients (90%), fever in 23 patients (76.76%), and other symptoms like chest tightness, headache, fatigue, gastrointestinal symptoms, etc., in 10 patients (33.33%). Documented maximum body temperature was found to be more than 100°F in 21 patients (70%), 98.6 to 100°F in two patients (6.67%), and less than 98.6°F in seven patients (23.33%). In the present study, 14 patients (46.67%) had underlying chronic medical illnesses inclusive of diabetes mellitus in 10 patients (33.33%), hypertension in six patients (20.00%), coronary artery disease in two patients (6.67%), and pulmonary disease in one patient (3.33%).

Arterial blood gas analysis done at presentation before TCZ infusion showed an average SpO₂ at room air to be 86.24% (86.24% ± 4.1) and average PF ratio to be 205.41 (205.41 ± 46.68). Prior to the infusion of TCZ, 34.48% of patients had SpO₂ less than 85% while 55.17% of patients had SpO₂ between 85 and 90% and 10.34% of patients had SpO₂ more than 90%. PF ratio was observed less than 150 in 13.33% of patients, 150 to 200 in 60% of patients, and more than 250 in 26.27% of patients. All patients of the study population required FiO₂ to maintain SpO₂ of more than 95% with an average requirement for FiO₂ being 59.93% (59.93% ± 19.57) prior to treatment. Of the study population, 24 patients (80%) were included in the severely ill category while the remaining six patients (20%) were included in the critically ill category. Laboratory investigations of patients were recorded with mean hemoglobin to be 13.60 gm/dL (13.60 ± 0.80), TLCs 7.27/mm³ (7.27 ± 2.52 mm³), and platelet counts 2.40 Lac/μL (2.40 ± 0.78 Lac/μL). Serum levels of IL-6 were found to be raised in all selected patients with mean values of 206.56 pg/mL (206.56 ± 142.72) [Reference range for normal value = 0–5.9 pg/mL]. It was observed that 90% of patients had an extremely elevated IL-6 level in the range of more than 10 times the upper limits of normal (ULN). All selected patients were admitted to the intensive care unit with oxygen support to maintain adequate oxygenation at tissue levels. Mode of oxygenation included a low-flow mask in six patients (20%), high-flow mask in 18 patients (60%), NIV in five patients (16.67%) while one patient (3.33%) required invasive ventilation. Twelve patients of 30 had undergone an HRCT chest that showed a CT severity score of less than 15 in 33.33% of patients, 15 to 20 in 50% of patients, and more than 20 in 16.67% of patients with an average CT severity score of 16.16 (16.16 ± 3.99).

After TCZ Infusion (Day 1 to Day 7) (Tables 2, 3 and Fig. 1)

A serial follow-up of data of all patients was done inclusive of maximum body temperature, SpO₂, PaO₂, PF ratio, requirement of FiO₂, mode of oxygenation, and serum levels of IL-6 at days 1, 3, 5, and 7 of TCZ infusion. In the present follow-up study, after TCZ infusion, maximum body temperature declined significantly with a mean body temperature of 99.32°F on day 1, 97.96°F on day 2, 97.7°F on day 5, and 97.6°F on day 7 ($t = 6.324, p < 0.001$). SpO₂ improved significantly after TCZ therapy with mean SpO₂ to be 89% on day 1, 92% on day 3, 96% on day 5, and 98% on day 7 ($t = 13.26, p < 0.001$). PF ratio was significantly increased after TCZ infusion with the levels being in the range of 240 at day 1, 300 at day 3, 357 at day 5, and 392 at day 7 ($t = 13.56, p < 0.001$) with a progressive decline in the requirement of FiO₂. Serum levels of IL-6 showed dramatic variations with initially raised IL-6 levels followed by a further decline in the mean value of 298.4 pg/mL at day 1, 305.9 pg/mL at day 3, 180.9 pg/mL at day 5, and 84.5 pg/mL at day 7 ($t = 13.33, p < 0.001$). Mode of oxygenation dramatically lightened after TCZ therapy with one patient being weaned off from NIV on day 1 of TCZ and two patients being weaned off from NIV on day 2. Only 21.43% of patients remained oxygen dependent with a low-flow mask at the end of day 7. The average CT severity score also dramatically reduced after TCZ infusion from 16.16 to 7.08 (Fig. 2).

Outcome (Table 1)

In the present study, 28 severely or critically ill patients recovered and were discharged from the hospital with an average time of 12.25 days (12.25 ± 4.95) of hospital stay. The average duration of seroconversion (time duration of first positive RT-PCR to first negative RT-PCR for COVID-19) was 10.08 days (10.08 ± 4.06). Two patients died in the early phase of study on day 1 who were critically ill at the time of TCZ infusion with type I respiratory failure.

DISCUSSION

In the present study, the efficacy of TCZ therapy in severely or critically ill COVID-19 patients was assessed. Luo et al. had reported similar disease-ameliorating findings, suggestive of TCZ therapy being an effective treatment option for COVID-19 patients, predisposing to cytokine storms.¹⁰ Findings of the present study support the efficacy of TCZ infusion in amelioration and/or management of cytokine storm (IL-6) induced by COVID-19. The SARS-CoV-2 virus replicates rapidly triggering a storm characterized

Table 2: Impact of TCZ on the clinical status of patients (day 0 for before TCZ infusion and day 1 to day 7 for after TCZ transfusion)

Characteristics	Day 0	Day 1	Day 3	Day 5	Day 7	Paired t-test Day 0 v/s Day 1	Paired t-test Day 0 v/s Day 3
Maximum temperature	100.8°F	99.32°F	97.96°F	97.7°F	97.6°F	$t = 6.324, p < 0.001$	$t = 8.869, p < 0.001$
Oxygen saturation at room air (SpO ₂)	86%	89%	92%	96%	98%	$t = 13.26, p < 0.001$	$t = 21.23, p < 0.001$
PaO ₂ at room air	43.6	50.4	63	75	82.4	$t = 12.23, p < 0.001$	$t = 20.28, p < 0.001$
PF ratio	208	240	300	357	392	$t = 13.56, p < 0.001$	$t = 20.28, p < 0.001$
FiO ₂ requiring to maintain SpO ₂ >95%	60%	48%	34%	27%	22%	$t = 14.48, p < 0.001$	$t = 16.94, p < 0.001$
IL-6	206.7	298.4	305.9	180.9	84.5	$t = 13.33, p < 0.001$	$t = 7.26, p < 0.001$
Number of patients on oxygen support	100%	100%	85.71%	50%	21.43%		
Average CT severity score	16.16	-	-	-	7.08		

Abbreviations: *t*, value of paired *t*-test; *p* values indicate differences between diabetes and non-diabetes patients, $p < 0.05$ was considered statistically significant; PaO₂, partial pressure of oxygen in arterial blood sample; PF ratio, PaO₂/FiO₂ ratio; CT, computerised tomography

Table 3: Line listing for the mode of oxygenation and serum level of IL-6 in serial follow-ups (day 0 for before TCZ infusion and day 1 to day 7 for after TCZ transfusion)

Sl. No.	Oxygen support					IL-6 (reference range = 0–5.9 pg/mL)				
	Day 0	Day 1	Day 3	Day 5	Day 7	Day 0	Day 1	Day 3	Day 5	Day 7
1	NIV	HFM	HFM	LFM	-	240	345	415	232	110
2	HFM	HFM	LFM	-	-	215	365	310	201	72.5
3	HFM	HFM	HFM	LFM	-	347	415	459	344	105
4	HFM	HFM	LFM	-	-	116	206	234	106	12.5
5	LFM	LFM	LFM	-	-	78.1	124	332	79.8	56.4
6	HFM	LFM	LFM	-	-	104	116	98.6	102	84.5
7	NIV	NIV	HFM	HFM	LFM	415	520	608	406	205
8	HFM	HFM	LFM	LFM	-	182	248	269	179	150
9	LFM	LFM	LFM	-	-	146	135	110	146	89.6
10	HFM	HFM	HFM	LFM	-	209	314	389	201	108
11	HFM	HFM	LFM	LFM	-	314	432	509	356	98.8
12	HFM	LFM	LFM	HFM	-	110	219	302	95.3	54.1
13	HFM	HFM	HFM	HFM	LFM	281	402	464	270	165
14	HFM	HFM	HFM	LFM	LFM	85.9	193	172	78.4	29.5
15	NIV	HFM	HFM	HFM	LFM	468	598	560	455	198
16	NIV	NIV	HFM	HFM	LFM	372	437	468	360	189
17	InV	InV	-	-	-	589	691	-	-	-
18	HFM	HFM	LFM	-	-	74.8	151	201	70.9	56.1
19	HFM	LFM	LFM	-	-	56.5	108	107	52.4	8.4
20	HFM	LFM	LFM	-	-	32.6	110	91.3	31.8	20.5
21	LFM	LFM	-	-	-	21.9	56.2	64.6	16.5	15.9
22	HFM	HFM	LFM	-	-	115	202	188	79.6	64.5
23	LFM	LFM	-	-	-	106	214	219	103	46.8
24	LFM	LFM	-	-	-	129	265	284	120	56.9
25	HFM	HFM	LFM	LFM	-	233	371	360	215	104
26	NIV	InV	-	-	-	415	548	-	-	-
27	HFM	HFM	HFM	LFM	-	209	314	389	201	108
28	HFM	HFM	LFM	LFM	-	314	432	509	356	98.8
29	LFM	LFM	-	-	-	106	214	219	103	46.8
30	HFM	HFM	LFM	-	-	116	206	234	106	12.5

Abbreviations: IL-6, interleukin-6; HFM, high-flow mask; LFM, low-flow mask; NIV, noninvasive ventilation; InV, invasive ventilation

by increased levels of cytokines, such as IL-6. The raised IL-6 levels have been reported to closely correlate with the incidence of RNAemia and COVID-19-related mortality.¹¹ IL-6 is an important proinflammatory factor in the disease process of SARS-CoV-2, contributing to COVID-19-associated cytokine storm, inducing vascular permeability with impaired organ system function. The rationale for the use of anti-IL-6 receptor antibody TCZ in COVID-19 patients is based on the appreciation of the role of IL-6 in this disease and the experience with this drug in the treatment of cytokine release syndrome caused by chimeric antigen receptor-redirected T-cells.¹² Moreover, the treatment strategy of using antivirals alone in COVID-19 may not be sufficient to reverse such deteriorating effects of IL-6.

In the present study, the efficacy of TCZ therapy, an IL-6R inhibitor, in the therapeutic response of 30 patients with severely and critically ill COVID-19 disease was assessed. The available clinical data showed that symptoms and hypoxemia improved immediately post-treatment with TCZ in most of the patients, suggesting that TCZ could be an efficient therapeutic option for the treatment

of COVID-19. In the present study, all patients were symptomatic before the infusion of TCZ with cough, shortness of breath, and fever. All patients of the study group had features of hypoxemia with reduced SpO₂ and PaO₂ with subsequently increased requirement of FiO₂ for all such patients before the infusion of TCZ therapy. The majority of patients required a high mode of oxygenation including a high-flow mask and NIV as these patients could not be maintained on a low-flow mask. Eighty percentage of patients were severely ill while the remaining 20% were critically ill. As for the laboratory investigations, the mean value of hemoglobin, TLCs, and platelet counts were found to be within normal limits. Zhang, chi et al. (2020) in their study had suggested that IL-6 could play an important role in cytokine release syndrome and, if the signal transduction pathway of IL-6 could be blocked, a new definitive treatment for severe COVID-19 patients could be in the offing.¹³ The present study showed that IL-6 was raised in all patients with the majority of patients (90%) having an extremely raised serum level of IL-6 of the order of more than 10 times of ULN. IL-6 can be used to evaluate the severity of the infection and predict prognosis. IL-6 monoclonal

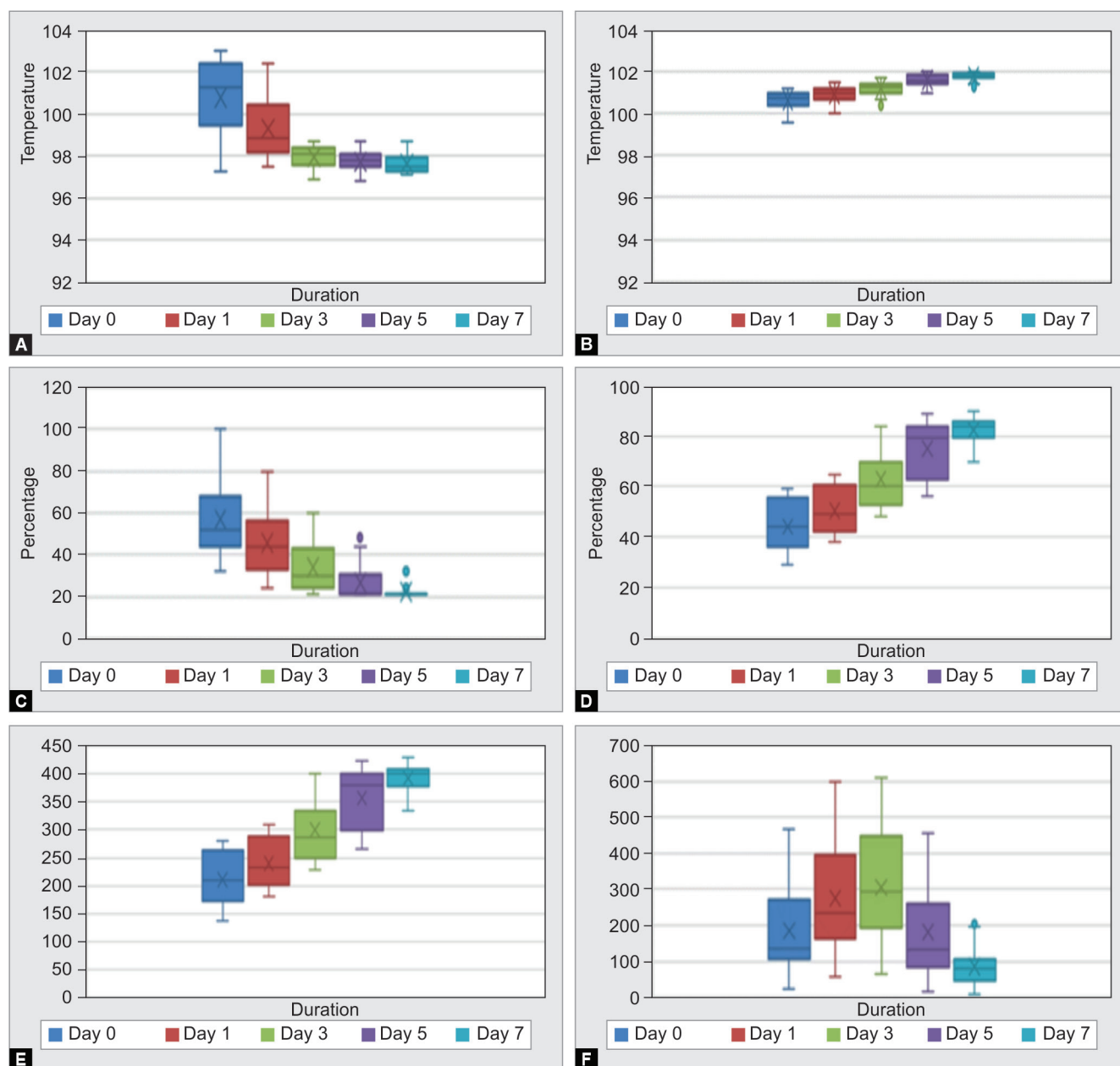


Fig. 1: The values of maximum body temperature, oxygen saturation at room air (SpO₂), concentration of inhaled oxygen (FiO₂), partial pressure of oxygen in blood (PaO₂) at room air, PaO₂/FiO₂ (PF) ratio, and serum level of IL-6 before and after the treatment with tocilizumab (TCZ) of 30 patients with COVID-19. (A) Maximum body temperature decreased significantly after treatment with TCZ and returned to normal in all patients. (B) SpO₂ improved with TCZ and returned to normal in all patients. (C) Concentration of FiO₂ significantly reduced after TCZ infusion and the majority of patients weaned off oxygen and returned to room air. (D and E) PaO₂ and PF ratio were significantly improved with the infusion of TCZ and returned to normal in nearly all patients. (F) IL-6 had a dramatic variation after TCZ transfusion with an initial peak spike followed by a reduction in the serum level of IL-6 after three days

antibody-directed COVID-19 therapy (TCZ) after its use in clinical trials has recently been incorporated into COVID-19 management guidelines, especially with extremely raised IL-6. TCZ can specifically bind to sIL-6R and mIL-6R and inhibit signal transduction and the drug is in use for rheumatoid arthritis.⁸ TCZ therapy initiated based on the serum level of IL-6 (manifold increased) and HRCT chest findings of diffuse, bilateral, homogeneous with peripheral-predominant ground-glass opacities with higher mean CT severity scores has the potential to decrease the mortality of COVID-19.

All patients were treated with a single prescribed dose of TCZ and followed sequentially for their clinical status, blood gas analysis, FIO₂ requirement, mode of oxygenation, and serum level of IL-6. Xu, Xiaoling et al. (2020) suggest that TCZ improved the clinical outcomes immediately in severe and critical COVID-19 patients and is seemingly an effective treatment to reduce mortality.¹⁴ All patients exhibited a dramatic reduction in maximum body temperature, even on the next day of TCZ infusion, with a further serial reduction of temperature that became normal within three

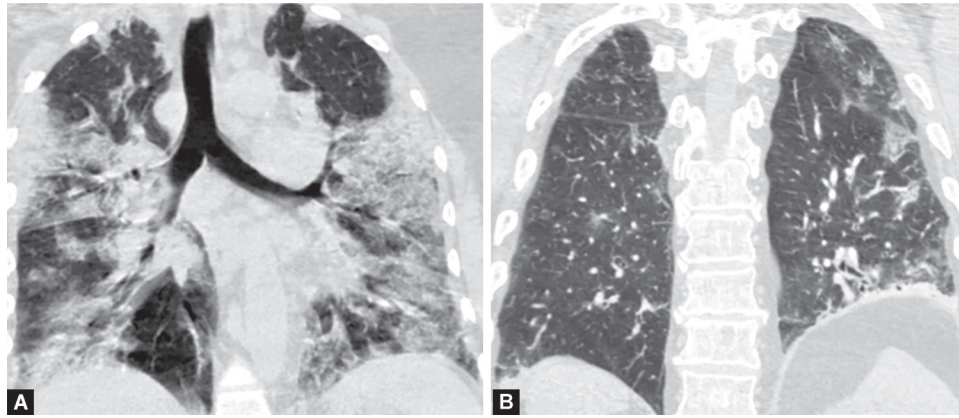


Fig. 2: HRCT chest of a 52-year-old male with severe COVID-19 disease. (A) Before TCZ transfusion showed bilateral diffuse ground-glass opacities with a CT severity score of 20/25; (B) After TCZ transfusion with a clinical improvement, suggestive of reduced opacities with a CT severity score of 9/25

days postinfusion. SpO₂, a rapid reflection of hypoxemia, improved immediately after TCZ infusion with the mean SpO₂ becoming more than 95% on day 5. PF ratio also increased immediately just after the infusion of TCZ therapy with the PF ratio being 300 on day 3. The mode of oxygenation also dramatically lightened after TCZ therapy with one patient being weaned off from NIV on day 1 of TCZ while two patients were weaned off from NIV on day 2. The requirement of high-flow oxygenation was also reduced and the majority of patients were shifted to a low-flow mask in follow-up of TCZ infusion. On day 7, only 21% of patients were oxygen dependent and the remaining patients did not require supplemental oxygen and were maintained on room air. In the follow-up HRCT scan of the chest on day 7, the majority of patients showed decreased ground-glass haziness and increased consolidation with reduced CT severity scores. Serum level of IL-6 showed a dramatic variation after infusion of TCZ with initially raised values of IL-6 followed by reduction spread across 3 to 5 days. IL-6 is mainly eliminated via IL-6R-mediated clearance.¹⁵ Binding of TCZ to IL-6R inhibits receptor-mediated clearance of IL-6, leading to its accumulation in serum, which is the likely explanation for raised IL-6 levels in TCZ-treated COVID-19 patients in the present study followed by a gradual decrease of IL-6 levels in the serum that could be partly due to inhibition of inflammatory activity so induced by TCZ, leading to stabilization and/or improvement of clinical outcomes. Two patients succumbed to life in the early phase of disease probably prior to the onset time so needed for a response of TCZ therapy to take place and the remaining patients were discharged within two weeks post-TCZ infusion. Henceforth, TCZ that acts by blocking of IL-6-associated febrile and inflammatory storm response could probably be effectively used to treat severe or critical patients of COVID-19.

CONCLUSION

COVID-19-infected patients with extremely high IL-6 levels are definitely at a higher risk of severe and fatal infection due to an increased inflammatory overdrive induced by cytokine storm, leading to greater mortality. IL-6 is the key molecule of cytokine release syndrome; therefore, IL-6R antagonist TCZ may be an important drug to save patients' lives. TCZ improves the clinical symptoms and oxygenation in severely or critically ill COVID-19 patients and TCZ could act as an effective definitive management protocol in such severely and critically ill COVID-19 patients and could provide a therapeutic window for such potentially fatal infectious diseases.

ACKNOWLEDGMENT

I would like to thank the anonymous referees for their useful suggestions. I would like to thank my professionals Dr. Abhishek Agrawal, Dr. C. L. Nawal, Dr. S. Banerjee, Dr. Prakash Keswani, Dr. Sunil Mahavar, Dr. R. S. Chejara, Dr. Vidyadhar Singh, Dr. Kapil, Dr. Amitabh Dube, Dr. Vishal Gupta, Dr. Meenu Bagarhatta, and the team of Department of General Medicine S.M.S. Medical College and Attached Group of Hospital, Jaipur for their valuable support. and Department of Radiodiagnosis for providing radiological information of COVID-19 patients.

Limitation: There are several limitations in this study. The number of patients was limited and needs to have been studied on a large patient cohort. It is a single-center observational study and a significant bias could have possibly existed. HRCT chest data were not available for all patients.

Ethical approval: This study was approved by the ethical and research committee of S.M.S. Medical College and Hospital, Jaipur, India.

Author contributions: S. Bhandari and G. Rankawat formulated the research questions, designed the study, developed the preliminary search strategy, and drafted the manuscript; G. Rankawat and A. Singh collected and analyzed the data for the study. G. Rankawat wrote the manuscript. S. Bhandari conducted the quality assessment. All authors critically reviewed the manuscript for relevant intellectual content. All authors have read and approved the final version of the manuscript.

Availability of data and materials: Available from the corresponding author upon reasonable request.

ORCID

Sudhir Bhandari  <https://orcid.org/0000-0003-2387-917X>
Govind Rankawat  <https://orcid.org/0000-0003-3708-3068>
Ajeet Singh  <https://orcid.org/0000-0003-3461-6420>

REFERENCES

- Chen N, Zhou M, Dong X, Qu J, Gong F, Han Y, et al. Epidemiological and clinical characteristics of 99 cases of 2019 novel coronavirus pneumonia in Wuhan, China: a descriptive study. *Lancet* 2020;395(10223):507–513. DOI: 10.1016/S0140-6736(20)30211-7.

2. Hui DS, Azhar EI, Madani TA, Ntoumi F, Kock R, Dar O, et al. The continuing 2019-nCoV epidemic threat of novel coronaviruses to global health—the latest 2019 novel coronavirus outbreak in Wuhan, China. *Int J Infect Dis* 2020;91:264–266. DOI: 10.1016/j.ijid.2020.01.009. PMC 7128332. PMID 31953166.
3. Murthy S, Gomersall CD, Fowler RA. Care for critically ill patients with COVID-19. *JAMA* 2020;323(15):1499–1500. DOI: 10.1001/jama.2020.3633.
4. Lan J, Ge JW, Yu JF, Shan SS, Zhou H, Fan SL, et al. Crystal structure of the 2019-nCoV spike receptor-binding domain bound with the ACE2 receptor. 2020. Available from: <https://www.biorxiv.org/content/10.1101/2020.02.19.956235v1>. DOI: 10.1101/2020.02.19.956235.
5. Davies R, Choy E. Clinical experience of IL-6 blockade in rheumatic diseases—implications on IL-6 biology and disease pathogenesis. *Semin Immunol* 2014;26(1):97–104. DOI: 10.1016/j.smim.2013.12.002.
6. Wolf J, Rose-John S, Garbers C. Interleukin-6 and its receptors: a highly regulated and dynamic system. *Cytokine* 2014;70(1):11–20. DOI: 10.1016/j.cyto.2014.05.024.
7. Jones SA, Scheller J, Rose-John S. Therapeutic strategies for the clinical blockade of IL-6/gp130 signaling. *J Clin Invest* 2011;121(9):3375–3383. DOI: 10.1172/JCI57158.
8. Kaly L, Rosner I. Tocilizumab—a novel therapy for non-organ-specific autoimmune diseases. *Best Pract Res Clin Rheumatol* 2012;26(1):157–165. DOI: 10.1016/j.berh.2012.01.001.
9. Rodriguez-Morales AJ, Cardona-Ospina JA, Gutiérrez-Ocampo E, Villamizar-Peña R, Holguin-Rivera Y, Escalera-Antezana JP, et al. Clinical, laboratory and imaging features of COVID-19: a systematic review and meta-analysis. *Travel Med Infect Dis* 2020;34:101623. DOI: 10.1016/j.tmaid.2020.101623.
10. Luo P, Liu Y, Qiu L, Liu X, Liu D, Li J. Tocilizumab treatment in COVID-19: a single center experience. *J Med Virol* 2020;92(7):814–818. DOI: 10.1002/jmv.25801.
11. Chen X, Zhao B, Qu Y, Chen Y, Xiong J, Feng Y, et al. Detectable serum SARS-CoV-2 viral load (RNAemia) is closely correlated with drastically elevated interleukin 6 (IL-6) level in critically ill COVID-19 patients. *Clin Infect Dis* 2020:ciaa449. Available from: <https://academic.oup.com/cid/advance-article-abstract/doi/10.1093/cid/ciaa449/5821311> by guest on 01 June 2020. DOI: 10.1093/cid/ciaa449.
12. Kotch C, Barrett D, Teachey DT. Tocilizumab for the treatment of chimeric antigen receptor T cell-induced cytokine release syndrome. *Expert Rev Clin Immunol* 2019;15(8):813–822. DOI: 10.1080/17446666X.2019.1629904.
13. Zhang C, Wu Z, Li JW, Zhao H, Wang GQ. Cytokine release syndrome in severe COVID-19: interleukin-6 receptor antagonist tocilizumab may be the key to reduce mortality. *Int J Antimicrob Agents* 2020;55(5):105954. DOI: 10.1016/j.ijantimicag.2020.105954.
14. Xu X, Han M, Li T, Sun W, Wang D, Fu B, et al. Effective treatment of severe COVID-19 patients with tocilizumab. *Proc Natl Acad Sci U S A* 2020;117(20):10970–10975. DOI: 10.1073/pnas.2005615117.
15. Nishimoto N, Terao K, Mima T, Nakahara H, Takagi N, Takeuchi T. Mechanisms and pathologic significances in increase in serum interleukin-6 (IL-6) and soluble IL-6 receptor after administration of an anti-IL-6 receptor antibody, tocilizumab, in patients with rheumatoid arthritis and Castleman disease. *Blood* 2008;112(10):3959–3964. DOI: 10.1182/blood-2008-05-155846.