

# Staphylococcal Pyopericardium: A Rare and Fatal Complication Following a Common Viral Disease

Utpal Sarma<sup>1</sup>, Vipul Mishra<sup>2</sup>, Imliwati Aier<sup>3</sup>, Veena Boswal<sup>4</sup>, Jyoti Goyal<sup>5</sup>

**Keywords:** Dengue fever, Pyopericardium, Staphylococcal infection.

*Indian Journal of Critical Care Medicine* (2021); 10.5005/jp-journals-10071-23866

A 30-year-old male was presented to emergency department with 2 days history of high-grade fever and excruciating chest pain associated with chills and rigors. The pain was located in mid-chest and radiating to the left back. He is nonsmoker, nonalcoholic with no known comorbidity. Ten days earlier he had dengue seropositive (NS1 Ag) febrile illness and was discharged from hospital once fever subsided.

On admission, patient had BP of 140/90 mm of Hg, pulse rate 120/min (sinus rhythm), SpO<sub>2</sub>-98% on ambient air, and temperature of 102°F. Systemic examination showed chest was clear, heart sounds were normally audible, and no jugular venous engorgement. His chest X-ray on admission was normal. However on second day after admission, he developed respiratory distress requiring oxygen supplementation. A pericardial rub was audible and electrocardiogram showed ST changes. X-ray chest showed symmetrical enlargement of cardiac silhouette suggestive of pericardial effusion. 2D-echo confirmed the diagnosis of pericardial effusion (anterior 16 mm, posterior 12 mm, lateral 13 mm, RV anterior 7 mm). HRCT (high-resolution computed tomography) chest showed left-sided

<sup>1</sup>Department of Critical Care and Pulmonology, Nayati Multi Super Speciality Hospital, Mathura, UP, India

<sup>2</sup>Department of Critical Care, Pulmonology and Sleep Medicine, Nayati Multi Super Speciality Hospital, Mathura, UP, India

<sup>3,4</sup>Swami Rama Himalayan University of Medical Sciences, Dehradun, Uttarakhand, India

<sup>5</sup>Department of Internal Medicine, Nayati Medicity, Mathura, UP, India

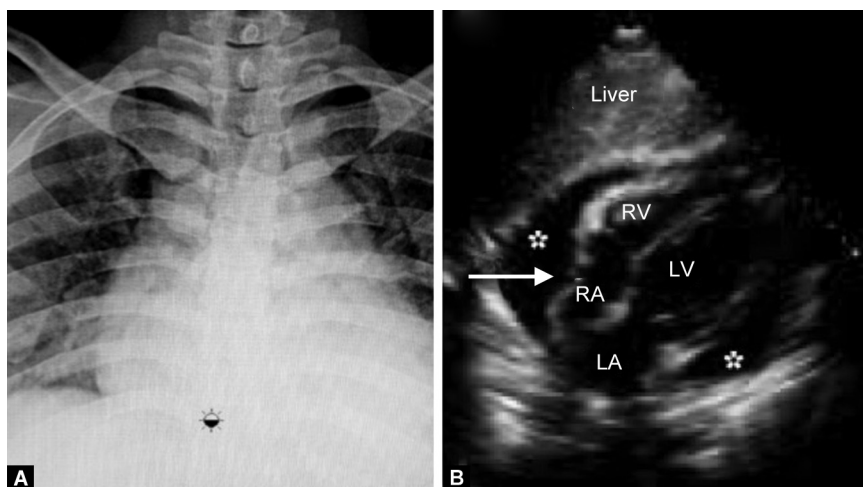
**Corresponding Author:** Utpal Sarma, Department of Critical Care and Pulmonology, Nayati Multi Super Speciality Hospital, Mathura, UP, India, Phone: +91 8811079816, e-mail: drutpalrgci@gmail.com

**How to cite this article:** Sarma U, Mishra V, Aier I, *et al.* Staphylococcal Pyopericardium: A Rare and Fatal Complication Following a Common Viral Disease. *Indian J Crit Care Med* 2021;25(6):739–741.

**Source of support:** Nil

**Conflict of interest:** None

**Contributor:** Dr. Utpal Sarma is the principal author. All co-authors have contributed towards the manuscript equally.



**Figs. 1A and B:** (A) X-ray chest showed symmetrical enlargement of cardiac silhouette suggestive of pericardial effusion (inverted water-bottle sign). (B) 2D-echo image showing moderate pericardial effusion (anterior 16 mm, posterior 12 mm, lateral 13 mm, RV anterior 7 mm)

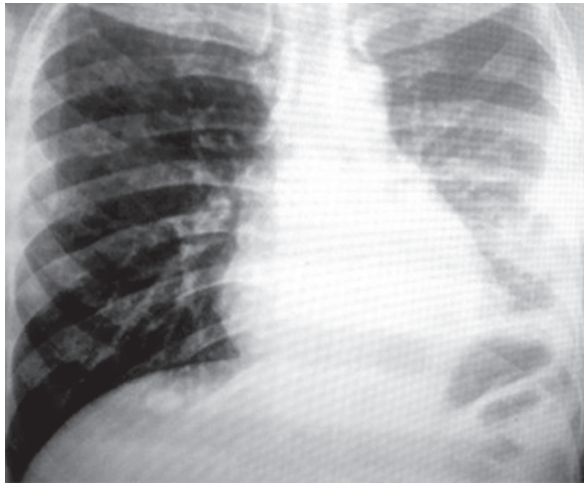


Fig. 2: Chest X-ray at the time of discharge of the patient

loculated pleural effusion, with a few thick-walled cavitory lesions in both lungs and hepatomegaly. Patient was started with intravenous continuous infusion of flucloxacillin infusion at 12 gm in a day and injection gentamycin once-daily dose. Two blood cultures grew coagulase-positive *Staphylococcus aureus*. Pericardial and pleural tapping under image guidance revealed exudative fluid with high cell count with neutrophilic predominance. Fever and chest pain resolved within 8 days. Repeat echocardiography after 1 week showed reduction in the volume of pericardial effusion. Pleural fluid at this time showed marked reduction in cells. After 10 days of intravenous

therapy, antibiotic was switched to oral cloxacillin 1 gm 6 hourly and continued for 4 weeks. The patient recovered completely during this period (Figs. 1 to 3).

Staphylococcal infection following dengue is infrequently reported.<sup>1-3</sup> One of the proposed mechanisms to explain coinfections in dengue is the damage of endothelial barrier rendering it possible to enter pathogens into circulation.<sup>4</sup> Acute pyopericardium is a potentially life-threatening illness associated with a mortality of up to 50%, with the majority of deaths due to cardiac tamponade (Table 1).

In our case, the diagnosis was made by echocardiography and biochemistry of aspirated pus from pleural and pericardium.

### ORCID

Utpal Sarma <https://orcid.org/0000-0001-9623-6138>

Vipul Mishra <https://orcid.org/0000-0002-6372-5610>

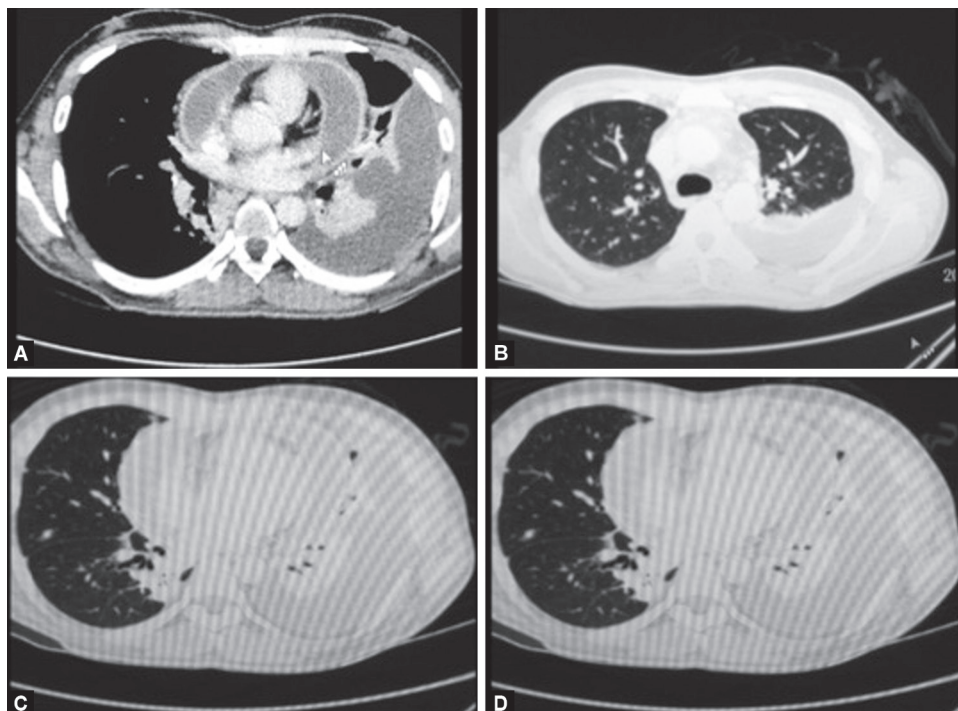
Imliwati Aier <https://orcid.org/0000-0001-7073-7890>

Veena Boswal <https://orcid.org/0000-0003-1529-0955>

Jyoti Goyal <https://orcid.org/0000-0002-4608-1809>

### REFERENCES

1. Miyata N, Yoshimura Y, Tachikawa N, Amano Y, Sakamoto Y, Kosuge Y. Cavity forming pneumonia due to *Staphylococcus aureus* following dengue fever. *Am J Trop Med Hyg* 2015;93(5):1055–1057. DOI: 10.4269/ajtmh.15-0045.
2. Araújo SA, Moreira DR, Veloso JM, Silva JO, Barros VL, Nobre V. Fatal Staphylococcal infection following classic Dengue fever. *Am J Trop Med Hyg* 2010;83(3):679–682. DOI: 10.4269/ajtmh.2010.10-0009.



Figs. 3A to D: HRCT chest showed left-sided loculated pleural effusion, with a few thick-walled cavitory lesions in both lungs

**Table 1:** Pericardial and pleural fluid analysis has shown predominantly neutrophilic leukocytosis

<i>Body fluids</i>	<i>Pretreatment</i>	<i>Posttreatment</i>
	TLC 150	40
Pleural	L 95%	92%
	N 5%	8%
	TLC 4155	
Pericardial	L 5%	
	N 95%	

L, lymphocyte; N, neutrophil; TLC, total leukocyte cell

3. Chai LY, Lim PL, Lee CC, Hsu LY, Teoh YL, Lye DC, et al. Cluster of Staphylococcus aureus and dengue co-infection in Singapore. Ann Acad Med Singap 2007;36(10):847–850. Available at: <https://www.annals.edu.sg/PDF/36VolNo10Oct2007/V36N10p847.pdf>
4. Lin CF, Lei HY, Shiau AL, Liu HS, Yeh TM, Chen SH, et al. Endothelial cell apoptosis induced by antibodies against dengue virus nonstructural protein 1 via production of nitric oxide. J Immunol 2002;169(2):657–664. DOI: 10.4049/jimmunol.169.2.657.