

Cardiac Pacing a Rare Cause of Ventilator Auto Triggering

Nithish Mukunthan M¹, Vimal Bhardwaj²

ABSTRACT

Ventilator auto triggering is an avoidable complication in ventilators, if left unnoticed can lead to deleterious effects. There are various causes for ventilator auto triggering. Though rare, there are some cardiac causes for inadvertent ventilator triggering. We report a case of 44-years-old male paced with atrial epicardial wires postcoronary artery bypass. The wires were close to the right phrenic nerve, causing the right diaphragm to contract in synchronization with the heartbeat. This caused ventilator auto triggering and ended up delivering inadvertent breaths. The pacemaker output was immediately reduced to the required minimum to continue pacing the heart and decrease phrenic nerve stimulation. This caused immediate changes in ventilator waveform and auto triggering was completely stopped and the patient could be successfully weaned off the ventilator. This case report emphasizes the need for timely recognition of alteration in ventilator waveforms and early intervention to avert any untoward events.

Keywords: Epicardial pacing, Flow trigger, Inadvertent triggering, Pacemaker, Respiratory alkalosis, Ventilator auto triggering, Ventilator waveforms.

Indian Journal of Critical Care Medicine (2022); 10.5005/jp-journals-10071-24219

HIGHLIGHTS

- Cardiac pacing is a rare but noteworthy cause of ventilator auto triggering.
- Happens when pacing wires are in close proximity to the right phrenic nerve.
- Timely recognition of auto trigger waveforms and early necessary interventions can avert untoward events.

INTRODUCTION

Mechanical ventilators may sometime deliver additional breaths to a patient due to unintentional triggering which is called ventilator auto triggering.¹ There are various reasons for auto triggering like water condensation in the circuit, stuck valves, leak in any portion of circuit or cuff leaks, decreased trigger settings in ventilator, inadvertent patient triggering, etc.^{2–4} Though rare, there are some cardiac causes for inadvertent ventilator triggering like cardiac oscillations and external pacemakers.^{5–7} Among pacemakers, the most prevalent cause is when atria are paced. This ventilator auto triggering causes multiple complications in patients like respiratory alkalosis, auto peeping, delayed ventilation, increased work of breathing, etc.^{8,9} We report a case of ventilator auto triggering in a case of postoperative coronary artery bypass who was put on atrial pacing and its management. It also gives us an insight into the need for timely recognition of alteration in ventilator graphs, troubleshooting the causes for variations in graphs, and early interventions to avert any untoward events.

CASE

A 44-year male known case of diabetes and chronic kidney disease was diagnosed with coronary artery disease and underwent a left anterior descending artery (LAD) endarterectomy plus coronary artery bypass with two grafts and two atrial and ventricular epicardial wires were placed (Fig. 1). Postoperatively the patient was received in the intensive care unit (ICU) intubated with

^{1,2}Department of Critical Care Medicine, Narayana Hrudayalaya, Bengaluru, Karnataka, India

Corresponding Author: Nithish Mukunthan M, Department of Critical Care Medicine, Narayana Hrudayalaya, Bengaluru, Karnataka, India, Phone: +91 9789666562, e-mail: nithishchat@gmail.com

How to cite this article: Mukunthan MN, Bhardwaj V. Cardiac Pacing a Rare Cause of Ventilator Auto Triggering. *Indian J Crit Care Med* 2022;26(5):643–645.

Source of support: Nil

Conflict of interest: None

minimal pressure. He was put on Mindray Synovet ES-mechanical ventilator on pressure regulated volume control mode with fractional inspiratory oxygen concentration (FiO₂)—40%, tidal volume—450 mL, flow trigger—2.0, positive end expiratory pressure (PEEP)—5, respiratory rate—14/minute. He was deeply sedated and ventilated overnight.

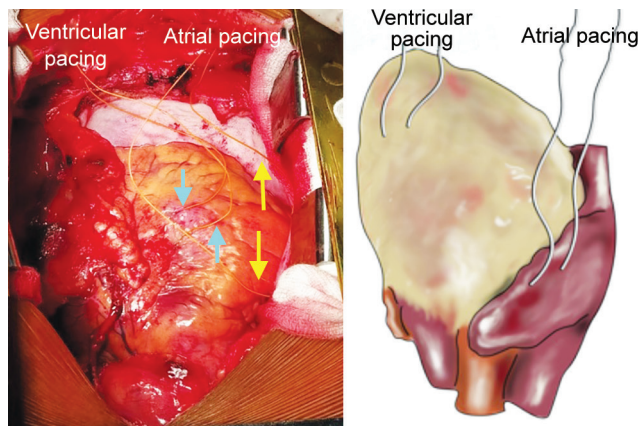


Fig. 1: Intraoperative placement of two atrial and ventricular epicardial wires

In the night he was started on atrial pacing for sinus bradycardia with a temporary cardiac pacemaker with sensitivity—6 millivolt (mV), output—12 volt (V), rate—90/minute. The next day morning sedation was decreased and while the patient was planning for extubation, we noticed auto triggering of the ventilator. The flow-time and pressure-time scalar showed multiple triggers in both phases of respiration which was triggering inadvertent breaths. On further examination of the patient there was a spontaneous contraction of the diaphragm with each heartbeat (Video 1). We hypothesized that the current from the atrial pacing wires could be causing right phrenic nerve stimulation which runs close by causing this entire phenomenon. We decreased the pacemaker output from 12 to 4 V (Fig. 2) which immediately stopped the diaphragm contraction and the auto triggering thereby normalizing the ventilator graphs (Fig. 3) (Video 2).

For confirmation we repeated the same maneuver with pressure support ventilation with flow trigger—2.0, pressure support—12, FiO_2 —40%, PEEP—5 and could elicit the same results (Fig. 4). Finally, the pacemaker output was reduced to 4 V and the patient was put on pressure support ventilation and extubated at the earliest avoiding any untoward complications.



Fig. 2: Reducing the pacemaker output from 12 to 4 V

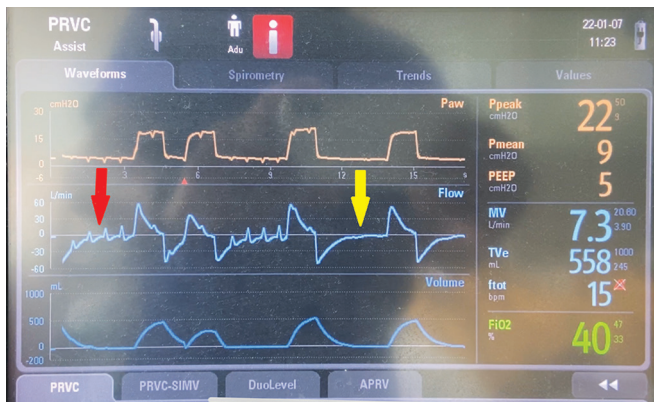

Fig. 3: The waveform is in pressure-regulated volume control mode. The red arrow shows the auto triggering waveforms with 12 V pacemaker output and the yellow arrow shows the resolution of waveforms once output was reduced to 4 V

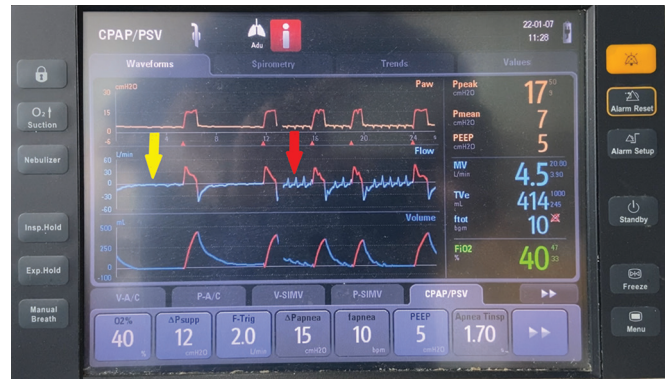

Fig. 4: Waveform in pressure support ventilation mode. The red arrow shows the auto triggering waveforms with 12 V pacemaker output and the yellow arrow shows the resolution of waveforms once output was reduced to 4 V

DISCUSSION

This case report demonstrates the importance of timely recognition of ventilator auto triggering and rectifying the cause for it to prevent untoward complications and delayed weaning. Artificial pacemakers are used to depolarize the atria and/or ventricle and make them contract. Usually, in post-cardiac surgery, atrial pacing is the most common form of pacing.⁷ In many cases the epicardial atrial pacing leads are kept close to the right phrenic nerve intraoperatively for better sensing.¹⁰ And postoperatively for better pacing, it is a common practice to keep the output higher as there may be surrounding tissue injury around the pacing leads resulting in variable energy output.¹¹ All these end up stimulating the right phrenic nerve and causing right diaphragm contraction and causing ventilator auto triggering. Such auto triggering can result in many complications like hyperventilation, respiratory alkalosis, auto peeping, hypotension, decreased urine output, delayed weaning, increased work of breathing, etc.^{8,9}

Bedside ventilator waveform analysis is an important skill for intensivists. By timely interpretation of graphs and decreasing the pacemaker output to the minimum necessary to maintain cardiac contraction, all the complications of inadvertent ventilator auto triggering were successfully averted.

CONCLUSION

Cardiac pacing as a cause of ventilator auto triggering is a very rare case scenario but clinically significant as failure to diagnose may cause complications that could have been avoided otherwise. This case report also emphasizes the importance of bedside recognition of various ventilator waveforms for early intervention and good patient outcomes.

SUPPLEMENTARY MATERIAL

All the supplementary videos are available on www.ijccm.org.

Video 1: Spontaneous diaphragmatic contraction corresponding to each heartbeat triggered by the pacemaker with 12 V output

Video 2: Waveforms in pressure regulated volume control mode showing auto triggering with 12 V pacemaker output which resolves to regular waveforms once the output is reduced to 4 V

ORCID

Nithish Mukunthan M <https://orcid.org/0000-0003-4252-2766>

Vimal Bhardwaj <https://orcid.org/0000-0003-4273-2771>

REFERENCES

1. France TE, Garnett AR, Grooms D. Inadvertent triggering of the ventilator caused by surgically placed pacer wires. *Respir Care* 2012;57(8):1334–1336. DOI: 10.4187/respcare.01378.
2. Pachisia AV, Bhattacharyya S. Post-cardiac arrest ventilator triggering. *Indian J Crit Care Med* 2019;23(4):196. DOI: 10.5005/jp-journals-10071-23155.
3. Sasso C. Triggering of the ventilator in patient-ventilator interactions. *Respir Care* 2011;56(1):39–48. DOI: 10.4187/respcare.01006.
4. Schawb RJ, Schnader J. Ventilator autocycling due to an endotracheal tube cuff leak. *Chest* 1991;100(10):1172–1173. DOI: 10.1378/chest.100.4.1172.
5. Kalaria N, Gupta A, Goila A, Sood R. Cardiogenic oscillation induced ventilator autotriggering. *J Neuroanaesthesiol Crit Care* 2015;2(02):134–135. DOI: 10.4103/2348-0548.154239.
6. Imanaka H, Nishimura N, Takeuchi M, Kimball R, Yahagi N, Kumon K. Autotriggering caused by cardiac oscillation during flow-triggered mechanical ventilation. *Crit Care Med* 2000;28(2):402–407. DOI: 10.1097/00003246-200002000-00019.
7. Khan AA, Nash A, Ring NJ, Marshall AJ. Right hemidiaphragmatic twitching: a complication of bipolar atrial pacing. *Pacing Clin Electrophysiol* 1997;20(6):1732–1733. DOI: 10.1111/j.1540-8159.1997.tb03550.x.
8. Oakes D. Clinical practitioner's pocket guide to respiratory care. Old Town, ME: Health Educator Publications; 2000. p. 2–14.
9. Sager JS, Eiger G, Fuchs BD. Ventilator auto-triggering in a patient with tuberculous bronchopleural fistula. *Respir Care* 2003;48(5):519–521. PMID: 12729469.
10. Wells WJ, Batra AS. Management of phrenic nerve stimulation caused by epicardial pacemaker leads in children. *Ann Thorac Surg* 2003;76(5):1757–1758. DOI: 10.1016/s0003-4975(03)00557-5.
11. Safavi-Naeini P, Saeed M. Pacemaker troubleshooting: common clinical scenarios. *Tex Heart Inst J* 2016;43(5):415–418. DOI: 10.14503/THIJ-16-5918.