

Modified Technique of Percutaneous Tracheostomy Using Borescope Camera: A Case Series

Mohd Mustahsin¹, Amit Srivastava², Jay Manchanda³, Ravi Kaushik⁴

ABSTRACT

Percutaneous dilatational tracheostomy (PDT) is a routinely performed procedure in the intensive care unit (ICU). Bronchoscopy guidance is recommended which requires expertise to use it, and also it is not readily available in all ICUs. Moreover, it can lead to carbondioxide (CO₂) retention and hypoxia during the procedure. To overcome these issues, we are using a waterproof 4 mm borescope examination camera in place of a bronchoscope which allows continuous ventilation, and real-time images of the tracheal lumen can be viewed on a smartphone or a tablet during the procedure. These real-time images can be transmitted wirelessly to a control room where experts can monitor and guide the junior staff performing the procedure. We are reporting successful use of the borescope camera during PDT.

Keywords: Bronchoscopy, Hypercapnia, Hypoxia, Percutaneous dilatational tracheostomy.

Indian Journal of Critical Care Medicine (2022): 10.5005/jp-journals-10071-24265

Sir,

Critically ill patients require tracheostomy to facilitate secretion removal, weaning from ventilator, prevent laryngeal injury, minimize the sedation requirement, and improve patient comfort.¹ Percutaneous dilatational tracheostomy is preferred in ICU as it can be performed at bedside by an intensivist, has less risk of infections, and is cost effective.² Bronchoscope is recommended during PDT as it helps in visualization of the correct position of tracheal puncture and guidewire placement, thus avoiding complications like injury to the posterior tracheal wall.³ Bronchoscope is not easily available in limited-resource countries and has its own limitations including hypoxia and hypercarbia during the procedure. To overcome these issues, we are using an affordable borescope examination camera during PDT and reporting its successful use.

A 35-year male known case of hypertension was presented with complaints of loss of consciousness for 6 hours and was intubated in emergency. His vitals showed a temperature of 98.7°F, blood pressure (BP) of 150/88, heart rate (HR) of 88/min, and SpO₂ of 98% on mechanical ventilation with FiO₂ 0.4. His laboratory investigations were unremarkable. CT brain showed multiple hemorrhagic lesions. He was started on an antibiotic, mannitol, and other supportive treatment in ICU.

On Day 7, the decision of PDT was taken to wean him from the ventilator. Written informed consent was obtained, a pre-procedure ultrasound neck was done to rule out any major vessel in tracheostomy field, and the puncture site was marked. The borescope camera was washed with water and placed in 2% glutaraldehyde solution before each procedure. After positioning the patient, the 4 mm borescope camera (Inskam™) with a 2 m cable was inserted through the catheter mount and connected to the tablet via USB type C (Fig. 1A). The real-time image from the camera was viewed on the tablet using the Inskam application freely downloadable from the google play store (Fig. 1B). The screen of the tablet was shared with the control room computer, where the senior intensivist was sitting and monitoring the procedure. The camera was advanced until distal tip of endotracheal tube (ETT), and the tube was withdrawn until the cuff is positioned just below the vocal

^{1,2,4}Department of Anesthesiology and Critical Care, Era's Lucknow Medical College and Hospital, Lucknow, Uttar Pradesh, India

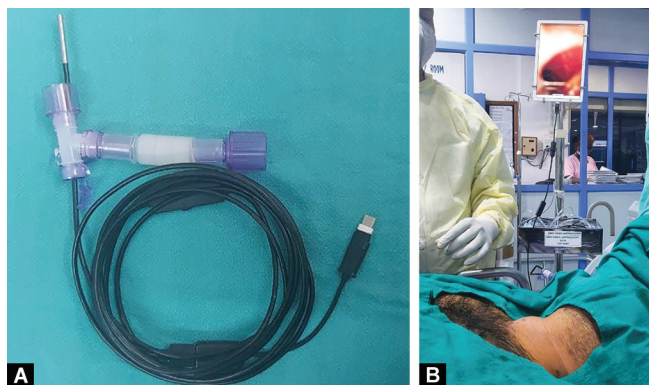
³Department of Pulmonary Medicine, Era's Lucknow Medical College and Hospital, Lucknow, Uttar Pradesh, India

Corresponding Author: Mohd Mustahsin, Department of Anesthesiology and Critical Care, Era's Lucknow Medical College and Hospital, Lucknow, Uttar Pradesh, India, Phone: +91 9871559131, e-mail: mustahsin.malik@gmail.com

How to cite this article: Mustahsin M, Srivastava A, Manchanda J, Kaushik R. Modified Technique of Percutaneous Tracheostomy Using Borescope Camera: A Case Series. *Indian J Crit Care Med* 2022;26(7):881–883.

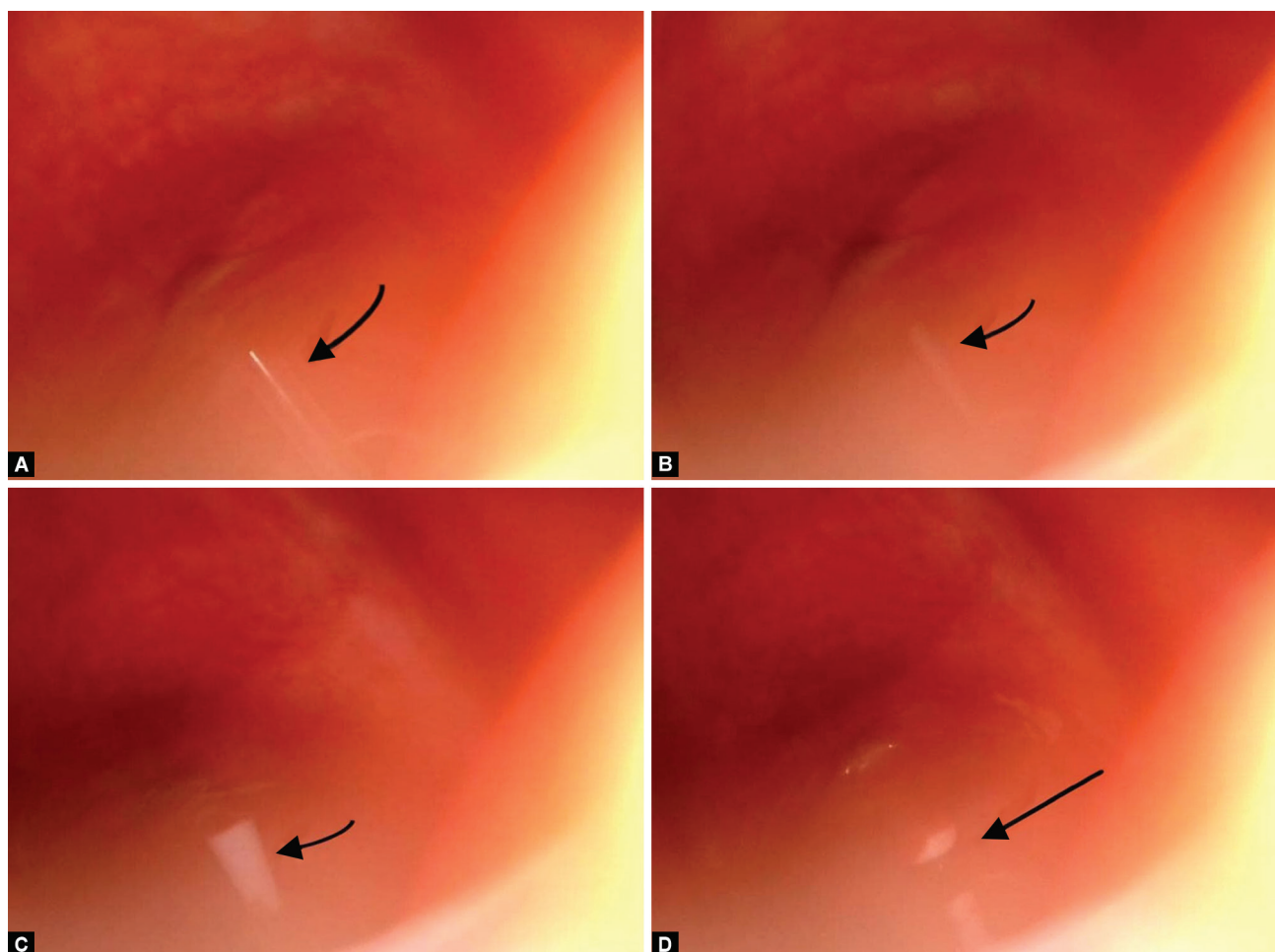
Source of support: Nil

Conflict of interest: None



Figs 1A and B: (A) Showing 4 mm borescope camera with 2 m long cable and catheter mount; (B) Showing borescope camera inserted through catheter mount and real-time visualization of trachea on a tablet

cords. Percutaneous tracheostomy was performed using single dilatation technique using Portex Ultraperc (Smith Medical™) under the vision, and the real-time recording of the procedure was saved (Fig. 2). The ETT was removed, and the ventilator circuit



Figs 2A to D: Real-time visualization of tracheostomy procedure. (A) Visualization of 15 G puncture cannula in the trachea; (B) Visualization of guidewire in the tracheal lumen; (C) Showing 12 F dilator entering in the trachea; (D) Visualization of single dilator entering into trachea from anterior tracheal wall

Table 1: Advantages and disadvantages of borescope over bronchoscope during PDT

	<i>Borescope</i>	<i>Bronchoscope</i>
Advantages	<ul style="list-style-type: none"> • Non-inferior view • Superior ventilation • Less hypercarbia and hypoxia • Low cost and low maintenance 	<ul style="list-style-type: none"> • Excellent view of the tracheal lumen • Examination of the distal airway is possible • Suctioning of secretions, bronchoalveolar lavage, and removal of mucous plugs is possible
Disadvantages	<ul style="list-style-type: none"> • Examination of the more distal airways is difficult • Suctioning of secretions is not possible 	<ul style="list-style-type: none"> • Compromises ventilation • Hypercarbia and hypoxia during the procedure • Costly, not easily available in all ICUs

was connected to the tracheostomy tube. No procedure-related complications were observed. On Day 8, the patient was weaned from the ventilator and shifted to the ward. We performed PDT in four cases using similar technique.

Our patients were successfully tracheostomized by using single dilatation technique and under vision using borescope examination camera. We didn't notice any complications related to the procedure, rather we found it to be more convenient with the following advantages:

- The 4.0 mm borescope examination camera was easily inserted into 7 mm or more ETT without the need to replace the ETT.
- The correct site of puncture was easily visualized and the view was non-inferior to bronchoscope.

- Real-time confirmation of midline tube position and avoidance of posterior tracheal wall injury.
- No significant air leak was noticed, and ventilation was not compromised during the procedure.
- There was no episode of hypoxia or hypercarbia during the procedure.
- Real-time recording of procedure was saved in phone/tablet for documentation and training.

Although there are many advantages of our technique over bronchoscopic guidance (Table 1), suctioning of secretions and more distal examination of trachea is not possible; however, we didn't require the need for this in our patients.

Various techniques of visualization of PDT have been proposed; however, bronchoscopic visualization is used in most of the centers of the world.^{4,5} Many intensivists avoid using bronchoscopes during PDT due to concerns of hypercarbia and hypoxia.⁶ The adult bronchoscope reduces the internal diameter of ETT and thus compromises the ventilation during bronchoscopy. We used 4 mm borescope camera that can easily pass through 7 mm or more internal diameter ETT without compromising the ventilation, and this is the reason why none of our patients developed hypercarbia or hypoxia during the procedure. Thus neurological patients and patients with pulmonary hypertension who require absolute avoidance of hypercarbia might benefit from our technique.

In conclusion borescope camera-guided PDT provides real-time continuous visualization of tracheal lumen without compromising ventilation, thus it is practical, affordable, and better alternative to bronchoscope during bedside PDT.

ORCID

Mohd Mustahsin  <https://orcid.org/0000-0003-2503-1906>

Amit Srivastava  <https://orcid.org/0000-0002-8096-9158>

Jay Manchanda  <https://orcid.org/0000-0003-1126-8136>

Ravi Kaushik  <https://orcid.org/0000-0002-0455-7805>

REFERENCES

1. Terragni P, Faggiano C, Martin EL, Ranieri VM. Tracheostomy in mechanical ventilation. *Semin Respir Crit Care Med* 2014;35(4): 482–491. DOI: 10.1055/s-0034-1383862.
2. Gupta S, Tomar DS, Dixit S, Zirpe K, Choudhry D, Govil D, et al. Dilatational percutaneous vs surgical tracheostomy in intensive care unit: a practice pattern observational multicenter study (DISSECT). *Indian J Crit Care Med* 2020;24(7):514–526. DOI: 10.5005/jp-journals-10071-23441.
3. Burrell T, Sampson B, Sundararajan K, Carter A. Percutaneous dilatational tracheostomy consensus statement. *Australian New Zealand Intensive Care Society (ANZICS)* 2014.
4. Gensemann J, Eichler L, Kähler S, Jarczak D, Simon M, Pinnschmidt HO, et al. Bronchoscopy versus an endotracheal tube mounted camera for the peri-interventional visualization of percutaneous dilatational tracheostomy—a prospective, randomized trial (VivaPDT). *Crit Care* 2017;21(1):330. DOI: 10.1186/s13054-017-1901-0.
5. Kumar P, Govil D, Patel SJ, Jagadeesh KN, Gupta S, Srinivasan S, et al. Percutaneous tracheostomy under realtime ultrasound guidance in coagulopathic patients: a single-center experience. *Indian J Crit Care Med* 2020;24(2):122–127. DOI: 10.5005/jp-journals-10071-23344.
6. Taha A, Omar AS. Percutaneous dilatational tracheostomy. Is bronchoscopy necessary? A randomized clinical trial. *Trends Anaesth Crit Care* 2017;15:20–24. DOI: 10.1016/j.tacc.2017.06.002.