

Tracheobronchial Injury: Role of Virtual Bronchoscopy

Amandeep Kaur¹, Vikram Pal Singh², Parshotam Lal Gautam³, Manender Kumar Singla⁴, M Ravi Krishna⁵

ABSTRACT

A tracheobronchial avulsion is a very rare and serious condition that occurs mostly due to blunt trauma chest caused by high-speed traffic accidents. In this article, we present a challenging case of a 20-year-old male who had a right tracheobronchial transection with carinal tear which was repaired on cardiopulmonary bypass (CPB) through right thoracotomy. Challenges faced and a review of literature will be discussed.

Keywords: Bronchopleural fistula, Cardiopulmonary bypass, Tracheobronchial injury.

Indian Journal of Critical Care Medicine (2022); 10.5005/jp-journals-10071-24271

HIGHLIGHTS

This is a rare case of life-threatening tracheobronchial injury (TBI). This case increases the awareness about the difficulties encountered during the induction and handling of such cases and the value of advanced preparation. Virtual bronchoscopy is another tool giving additional information for aiding in early diagnosis and management plan.

INTRODUCTION

Tracheobronchial injury is a potentially life-threatening condition. Blunt trauma to the chest and iatrogenic airway injury is the most common causes of tracheobronchial injuries, and this constitutes 1–2% of chest injuries.^{1,2} In these patients, it is important to recognize clinical signs and symptoms of TBI as conventional airway control may result in a catastrophic situation with failure to ventilate due to tension pneumothorax.³ In 60% of polytrauma patients, there is associated chest trauma and has a mortality of 20–25%.⁴ In this report, we will discuss a very rare case of tracheobronchial avulsion injury and its management.

CASE DESCRIPTION

In this report, we present a case of a 20-year-old man who was brought to the emergency room after being crushed between the car and a tractor. Following the initial examination, there was extensive surgical emphysema over the entire chest. Chest radiograph showed bilateral pneumothorax with bilateral multiple rib fractures (Fig. 1), following which bilateral chest tubes were inserted immediately, and chest X-ray after intercostal drains showed non-expansion of the right lung. The patient underwent urgent CT chest imaging, which showed bilateral pneumothorax with bilateral intercostal drains *in situ* and suspicion of right bronchial tear (Fig. 2). The patient was taken emergently to the operating room and planned for surgery under high-risk consent. Preoperative vitals showed SpO₂ of 88% on the reservoir bag mask with a pulse rate of 138/minutes and respiratory rate of 36/minutes. Because of suspected bronchial injury, we planned to do bronchoscope-guided awake intubation with standby CPB, but the patient was not co-operative. During induction, the patient had severe hypoxia and required rescue airway control with endotracheal intubation. He continued to deteriorate due to a

^{1,3–5}Department of Critical Care Medicine, Dayanand Medical College and Hospital, Ludhiana, Punjab, India

²Department of CTVS, Dayanand Medical College and Hospital, Punjab, India

Corresponding Author: Amandeep Kaur, Department of Critical Care Medicine, Dayanand Medical College and Hospital, Ludhiana, Punjab, India, Phone: +91 9779656700, e-mail: vikramandeep@gmail.com

How to cite this article: Kaur A, Singh VP, Gautam PL, Singla MK, Krishna MR. Tracheobronchial Injury: Role of Virtual Bronchoscopy. *Indian J Crit Care Med* 2022;26(7):879–880.

Source of support: Nil

Conflict of interest: None

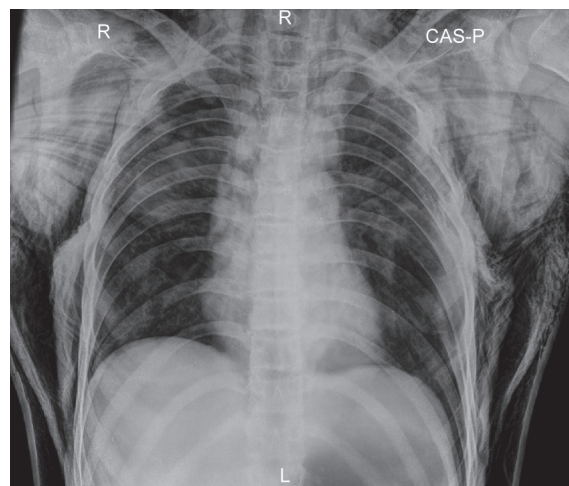


Fig. 1: Chest X-ray before insertion of intercostal drains

large bronchopleural fistula, and his condition worsened quickly to catastrophic hypotension. The patient was taken on CPB, and a right posterolateral thoracotomy was performed. Surgical findings showed right mainstem bronchus transection from trachea with carinal tear extending to right bronchus. An end-to-end anastomosis was done between the right main bronchus and the trachea. The postoperative course was uneventful, and the patient

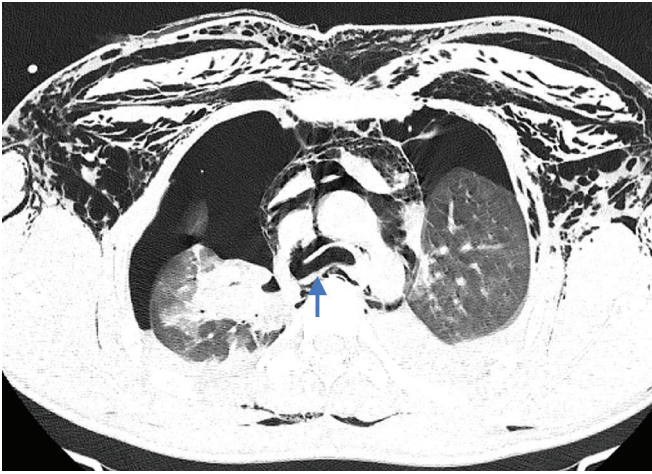


Fig. 2: CT chest at the level of carina before insertion of intercostal drains, arrow showing site of tracheal laceration

was discharged after a week. Postoperatively we reconstructed CT images for virtual bronchoscopy, which revealed the right bronchial injury.

DISCUSSION

Tracheobronchial injury is a rare clinical situation in which a missed diagnosis and conventional airway management can result in catastrophic ventilation failure. We report a very rare case of tracheobronchial avulsion due to blunt chest trauma caused by a road traffic accident. Motor vehicle accidents are the most common mechanism of these kinds of injuries.⁵ Few such cases of tracheobronchial avulsion due to blunt chest trauma have been reported.⁶

In this case report, the patient had a complete right tracheobronchial tear with carinal extension. Other mechanisms of TBI due to blunt trauma have been suggested by Kiser et al., who have classified them into three types—rupture of tissues due to reflex glottis closure, due to shearing forces at the cricoid cartilage and carina, and due to chest compression anteroposteriorly leading to the laceration at the level of the carina.⁷ Clinical presentation of tracheobronchial injuries can be nonspecific and include subcutaneous emphysema, pneumomediastinum, and pneumothorax. Our patient also presented with similar findings. Computed tomography has 85% sensitivity to detecting airway lesions.⁸ It may show mediastinal emphysema, fallen lung sign, separation in the tracheobronchial air column, or the exact location of the injury. Flexible bronchoscopy is the key to diagnosis in suspected patients and remains the gold standard.⁹ These major tracheobronchial injuries pose a challenging situation to the anesthesiologist. There was little discrepancy between virtual

bronchoscopy and operative findings. In such cases, surgical repair should be performed as early as possible.

Our patient respiratory distress, despite the insertion of bilateral intercostal drains, rendered a high index of suspicion of TBI. Early recognition of clinical signs, prompt diagnosis, appropriate airway management, and early surgical repair led to an improved outcome. If feasible, virtual bronchoscopy may give additional information to do better planning for anesthesia and surgery.

To conclude, TBI caused by blunt trauma is an uncommon life-threatening scenario. As Benjamin Franklin's quote, "If you Fail to Plan, You Are Planning to Fail". This case increases awareness about the difficulties encountered during the handling of such cases and the value of advanced preparation. Virtual bronchoscopy is another tool giving additional information for aiding in early diagnosis and helping in the management plan.

ORCID

Amandeep Kaur <https://orcid.org/0000-0002-9093-3132>

Vikram Pal Singh <https://orcid.org/0000-0001-8215-6508>

Parshotam Lal Gautam <https://orcid.org/0000-0002-7615-4781>

Manender Kumar Singla <https://orcid.org/0000-0002-2448-3057>

M Ravi Krishna <https://orcid.org/0000-0002-5360-3847>

REFERENCES

1. Farzanegan R, Alijanipour P, Akbarshahi H, Abbasidezfouli A, Pejhan S, Daneshvar A, et al. Major airways trauma, management and long term results. *Ann Thorac Cardiovasc Surg* 2011;17(6):544–551. DOI: 10.5761/atcs.0a.11.01679.
2. Goonasekera CDA, Esufali ST. Managing iatrogenic tracheal injuries. *Indian J Crit Care Med* 2005;9(2):88–91. DOI: 10.4103/0972-5229.17095.
3. Karmy-Jones R, Wood DE. Traumatic injury to the trachea and bronchus. *Thorac Surg Clin* 2007;17(1):35–46. DOI: 10.1016/j.thorsurg.2007.03.005.
4. Chu CPW, Chen PP. Tracheobronchial injury secondary to blunt chest trauma: diagnosis and management. *Anaesth Intensive Care* 2002;30(2):145–152. DOI: 10.1177/0310057X0203000204.
5. Raju KNJP, Anandhi D, Surendar R, Shetty A, Pandit VR. Blunt trauma neck with complete tracheal transection—a diagnostic and therapeutic challenge to the trauma team. *Indian J Crit Care Med* 2017;21(6):404–407. DOI: 10.4103/ijccm.IJCCM_103_17.
6. Cay A, Imamoğlu M, Sarihan H, Koşucu P, Bektaş D. Tracheobronchial rupture due to blunt trauma in children: report of two cases. *Eur J Pediatr Surg* 2002;12(6):419–422. DOI: 10.1055/s-2002-36857.
7. Kiser AC, O'Brien SM, Detterbeck FC. Blunt tracheobronchial injuries: treatment and outcomes. *Ann Thorac Surg* 2001;71(6):2059–2065. DOI: 10.1016/s0003-4975(00)02453-x.
8. Chen JD, Shanmuganathan K, Mirvis SE, Killeen KL, Dutton RP. Using CT to diagnose tracheal rupture. *AJR Am J Roentgenol* 2001;176(5):1273–1280. DOI: 10.2214/ajr.176.5.1761273.
9. Deja M, Menk M, Heidenhain C, Spies CD, Heymann A, Weidemann H, et al. Strategies for diagnosis and treatment of iatrogenic tracheal ruptures. *Minerva Anestesiol* 2011;77(12):1155–1166. PMID: 21602752.