

## Case Report



# Malarial pancreatitis: Case report and systematic review of the literature

Inderpaul Singh Sehgal, Ritesh Agarwal, Digambar Behera, Sahajal Dhooria

### Abstract

Malaria can cause a wide spectrum of clinical manifestations ranging from uncomplicated febrile illness to multiorgan failure. Pancreatitis is a rare complication of malaria with only a few reported cases. Herein, we describe a case of acute pancreatitis with multiorgan failure due to *Plasmodium falciparum* managed successfully with antimalarials and conservative treatment. We also perform a systematic review of literature for reports of acute pancreatitis due to *Plasmodium* infection.

**Keywords:** Abdominal pain, acute respiratory distress syndrome, malaria, multiorgan dysfunction, pancreatitis

### Access this article online

**Website:** [www.ijccm.org](http://www.ijccm.org)

**DOI:** 10.4103/0972-5229.171414

**Quick Response Code:**



## Introduction

Malaria is one of the most important protozoan parasitic infection of humans and remains endemic in India. It is responsible for 1.8% of cumulative deaths before the age of 70 years.<sup>[1]</sup> It is one of the common causes of acute febrile illness in endemic areas and can cause single or multiorgan dysfunction including acute renal failure, acute respiratory distress syndrome (ARDS), jaundice, myocarditis, hemolytic anemia, coma, and others.<sup>[2,3]</sup> Acute pancreatitis is a rare manifestation of malaria with only a few cases reported in literature. Herein, we report a case of acute pancreatitis and multiorgan dysfunction caused by *Plasmodium falciparum*. We also perform a systematic review of literature on acute pancreatitis caused by malaria.

## Case Report

A 40-year-old man presented with acute onset high-grade fever, jaundice, and abdominal pain of 10 days duration. He did not have any vomiting, passage

of clay-colored stools, or any alteration in his bowel habit. Three days before the presentation, the patient had also developed breathlessness, drowsiness, and decreased urine output. There was no cough, chest pain, or hemoptysis. There was no history of any seizures, sensory or motor complaints. The patient did not have any comorbidities or addictions. On examination, the pulse rate was 124 per min, respiratory rate 40 per min, blood pressure 100/60 mmHg, and temperature 101°F. Glasgow coma score was 10. Pallor and icterus were present. Auscultation of the chest revealed bilateral basal crackles. The abdomen was distended with epigastric tenderness and hepatosplenomegaly.

Investigations revealed anemia, thrombocytopenia, and neutrophilic leukocytosis with deranged renal and liver functions [Table 1]. Peripheral blood examination showed

This is an open access article distributed under the terms of the Creative Commons Attribution-NonCommercial-ShareAlike 3.0 License, which allows others to remix, tweak, and build upon the work non-commercially, as long as the author is credited and the new creations are licensed under the identical terms.

### From:

Department of Pulmonary Medicine, Postgraduate Institute of Medical Education and Research, Chandigarh, India

### Correspondence:

Dr. Sahajal Dhooria, Department of Pulmonary Medicine, Postgraduate Institute of Medical Education and Research, Chandigarh - 160 012, India.  
E-mail: [sahajal@gmail.com](mailto:sahajal@gmail.com)

**For reprints contact:** [reprints@medknow.com](mailto:reprints@medknow.com)

**How to cite this article:** Sehgal IS, Agarwal R, Behera D, Dhooria S. Malarial pancreatitis: Case report and systematic review of the literature. *Indian J Crit Care Med* 2015;19:743-6.

trophozoites of *P. falciparum* (parasite index 1.5%) and rapid diagnostic test (QDx Malaria Pv/Pf malaria card test, Piramal Healthcare Limited, India) for *P. falciparum* was positive. Hypoxemia ( $\text{PaO}_2/\text{FiO}_2$  ratio = 69) was present with bilateral alveolar opacities on chest radiograph suggesting ARDS [Figure 1]. Bacterial cultures of blood and endotracheal aspirate were sterile throughout the hospital stay. Serum amylase was 391 U/L and lipase was 753 U/L [Table 1]. Contrast enhanced computed tomography (CT) scan of the abdomen revealed evidence of pancreatitis with a modified CT score of 10 [Figure 2] and bedside index of

severity in acute pancreatitis (BISAP) score of 4. There were no gallstones on ultrasound or CT of the abdomen.

The patient was diagnosed as severe falciparum malaria with acute pancreatitis. He was electively intubated and mechanically ventilated. He was kept nil per oral and a nasogastric tube was placed. Intravenous artesunate (120 mg every 12 h for 3 days followed by 120 mg every 24 h) and oral doxycycline (200 mg/day in two divided doses) were administered. Despite treatment, there was progressive abdominal distension with the development of abdominal compartment syndrome (indicated by a high abdominal pressure of 28 cm of saline, hypotension, and worsening renal failure). Intravenous normal saline, vasopressors (noradrenaline and vasopressin), and intravenous meropenem were started. An abdominal drain was placed to decrease the intraabdominal pressure, and intermittent hemodialysis was performed.

Abdominal pressure decreased, fever abated, and hypotension resolved on the 5<sup>th</sup> day. Renal function improved and dialysis was stopped after six sessions. The patient was subsequently discharged after 4 weeks of hospitalization and continued to do well on follow-up.

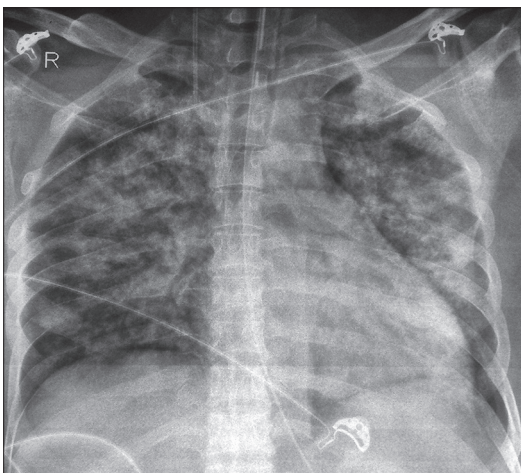
## Discussion

The case highlights that acute pancreatitis can occasionally complicate the course of falciparum malaria. We made a diagnosis of malaria-associated pancreatitis as the patient did not consume alcohol; there were no gallstones on abdominal imaging, no history of consumption of any drug known to cause pancreatitis and normal serum calcium with only mildly raised serum triglycerides. Although the exact mechanism of pancreatitis is unclear,

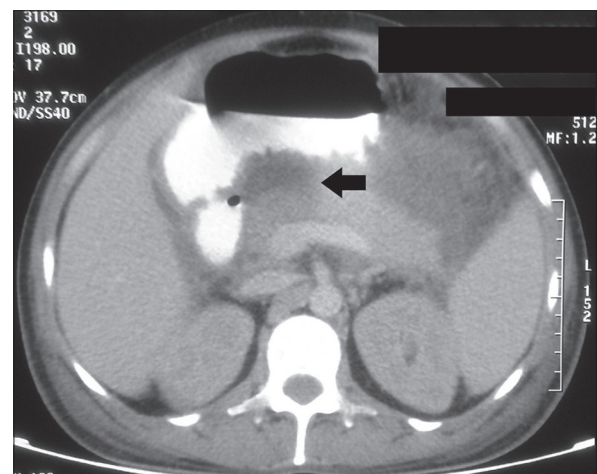
**Table 1: Clinical characteristics at baseline and discharge**

Parameter	Baseline	At discharge
Hemoglobin (g/dL)	8.0	12.8
Total leukocyte count (cells/mm <sup>3</sup> )	12,100	8000
Platelet count ( $\times 10^3/\text{mm}^3$ )	17	330
Blood urea (mg/dL)	290	54
Serum creatinine (mg/dL)	8.6	1.1
Serum albumin (g/dL)	2.2	3.5
Serum bilirubin (mg/dL)	30.0	2.3
Alanine transaminase (U/L)	23	22
Aspartate transaminase (U/L)	72	45
Alkaline phosphatase (U/L)	71	60
Serum calcium (mg/dL)	9.0	8.9
Serum LDH (U/L)	250	167
Serum triglycerides (mg/dL)	398	180
Serum amylase (U/L)	391	63
Serum lipase (U/L)	753	15
Serum procalcitonin ( $\mu\text{g/L}$ )	54.5	0.2
$\text{PaO}_2/\text{FiO}_2$ ratio	68.8	300.0
$\text{HCO}_3^-$ mmol/L	14.0	25.0
Blood culture	Sterile	Sterile
Tracheal aspirate culture	Sterile	Sterile
Intraabdominal pressure (cm of saline)	28.0	8.0
IgM (ELISA) <i>Leptospira</i>	Negative	
IgM (ELISA) for dengue virus	Negative	
PCR for <i>O. tsutsugamushi</i>	Negative	

ELISA: Enzyme-linked immunosorbent assay;  $\text{FiO}_2$ : Fractional inspired oxygen; LDH: Lactate dehydrogenase;  $\text{PaO}_2$ : Arterial partial pressure of oxygen; PCR: Polymerase chain reaction; S: Serum; U: Units; *O. tsutsugamushi*: *Orientia tsutsugamushi*



**Figure 1:** Chest radiograph showing bilateral infiltrates consistent with acute respiratory distress syndrome



**Figure 2:** Contrast enhanced computed tomography of the abdomen showing pancreatic necrosis

the possible reason can be obstruction of capillaries due to parasite-laden erythrocytes causing ischemic damage to pancreatic parenchyma or massive hemolysis associated with malaria.<sup>[4-6]</sup>

Pancreatitis as a complication of malaria is a rare entity with the first case reported in 1907.<sup>[7]</sup> A systematic review of the PubMed and EmBase databases using

the search string (“malaria” or “falciparum” or “vivax” or “malariae” or “ovale”) and “pancreatitis” yielded 18 reports (22 cases) on pancreatitis caused by malaria [Table 2].<sup>[4,8-24]</sup> The most common species responsible was *P. falciparum* (17/22), which was also the causative species in the index case. Abdominal pain was reported in all cases while icterus was seen in 12 cases. Abdominal pain in malaria can be due to

**Table 2: Studies reporting pancreatitis due to malaria**

Author (year)	Number of patients	Age (years)	Gender	Abdominal pain	Jaundice	Serum amylase (U/L)	Serum lipase (U/L)	Severity	Species	Parasite index (%)	Organ failure	Treatment given	Final outcome
Johnson et al. (1977) <sup>[20]</sup>	1	26	Male	Yes	Yes	NA	NA	NA	<i>P. falciparum</i>	NA	Pleural effusion	Antimalarial	Survived
Gurman et al. (1988) <sup>[8]</sup>	1	19	Female	Yes	Yes	NA	NA	NA	<i>P. falciparum</i>	2	ARDS	Quinine and tetracycline	Survived
Druml et al. (1991) <sup>[4]</sup>	1	25	Female	Yes	NA	651	NA	NA	NA	NA	Renal failure, altered sensorium, DIC	Antimalarial	Survived
Sarma and Kumar (1998) <sup>[9]</sup>	1	17	Male	Yes	Yes	2132	NA	Severe	<i>P. falciparum</i>	1.5	No	Quinine	Survived
Praetorius et al. (1999) <sup>[10]</sup>	1	67	Female	Yes	No	NA	NA	Severe	<i>P. falciparum</i>	10	Renal failure, ARDS	Mefloquine, quinine	Survived
Desai et al. (2001) <sup>[11]</sup>	2	40, 58	Male (1), female (1)	Yes (2/2)	Yes (2/2)	535 133	1329 1037	Moderate	<i>P. falciparum</i> (2/2)	0.5	Renal failure	Artemether, mefloquine, artesunate, doxycycline	Survived
Seshadri et al. (2008) <sup>[12]</sup>	1	21	Male	Yes	Yes	1712	5217	Severe	<i>P. falciparum</i> and <i>P. vivax</i>	45	Renal failure, subdural hematoma	Artesunate, doxycycline, quinine, cefepime	Survived
Badhal et al. (2009) <sup>[24]</sup>	1	33	Male	Yes	No	NA	NA	Severe	<i>P. falciparum</i>	1.9	Renal failure, DIC, hypotension, altered sensorium	Artesunate, quinine, doxycycline	Died
Kumar et al. (2010) <sup>[13]</sup>	1	35	Male	Yes	Yes	472	2460	Moderate	<i>P. falciparum</i>	60	No	Quinine, ceftriaxone	Survived
Thapa et al. (2010) <sup>[14]</sup>	1	13	Male	Yes	Yes	1,456	4562	Moderate	<i>P. falciparum</i>	4.5	Renal failure	Artesunate, mefloquine	Survived
Mandal et al. (2011) <sup>[15]</sup>	1	35	Male	Yes	Yes	783	2,225	Severe	<i>P. falciparum</i>	40	Renal failure	Artesunate, antibiotics	Died
Mohapatra and Gupta (2011) <sup>[16]</sup>	3	45, 28, 38	Male (2), female (1)	Yes (3/3)	Yes (1/3)	1200.5 2200.5 2050	608.6 860.6 960.8	Moderate to severe	<i>P. falciparum</i> (3/3)	6.2-9.2	Renal failure (1/3), altered sensorium (3/3)	Artesunate, antibiotics	Survived (3/3)
Sharma et al. (2012) <sup>[17]</sup>	1	17	Male	Yes	Yes	1234	NA	Severe	<i>P. vivax</i>	NA	Renal failure, hypotension	Antibiotics	Died
Atam et al. (2013) <sup>[18]</sup>	1	42	Female	Yes	No	1230	800	Severe	<i>P. vivax</i>	NA	ARDS, hypotension	Artesunate, imipenem	Died
Sharma and Kant (2013) <sup>[21]</sup>	2	62, 17	Female (1), male (1)	Yes (2/2)	No	11,000 9000	NA 400	Moderate	<i>P. falciparum</i> (2/2)	NA	No	Quinine	Survived (2/2)
Sundriyal et al. (2013) <sup>[22]</sup>	1	35	Male	Yes	No	756	414	Moderate	<i>P. vivax</i>	NA	No	Artesunate, clindamycin	Survived
Ghosh et al. (2014) <sup>[19]</sup>	1	40	Male	Yes	Yes	525	250	Moderate	<i>P. falciparum</i>	NA	No	Artesunate	Survived
Singh et al. (2014) <sup>[23]</sup>	1	24	Male	Yes	No	2800	1200	Moderate	<i>P. falciparum</i>	60	No	Artesunate	Survived
Index case	1	40	Male	Yes	Yes	398.8	391.7	Severe	<i>P. falciparum</i>	1.5	ARDS, renal failure, hypotension	Artesunate and doxycycline, imipenem	Survived

ARDS: Acute respiratory distress syndrome; DIC: Disseminated intravascular coagulation; NA: Not available; *P. falciparum*: *Plasmodium falciparum*; *P. vivax*: *Plasmodium vivax*

various causes such as acalculous cholecystitis, splenic infarction, splenic rupture, hepatitis, acute renal failure, and others. The review suggests that in patients with malaria presenting with abdominal pain, pancreatitis may also be considered as a possible etiology.

The diagnosis of malaria-associated pancreatitis is based upon clinical symptoms (abdominal pain, jaundice, abdominal tenderness, and guarding), laboratory investigations (elevated serum amylase and lipase are seen in 19/22 and 15/22 patients, respectively, in the systematic review), and radiology (ultrasound and contrast-enhanced CT abdomen) and is considered after the common causes of pancreatitis are excluded.

Pancreatitis in malaria might be associated with dysfunction of other vital organs such as renal failure ( $n = 9$ ), ARDS ( $n = 3$ ), hypotension ( $n = 2$ ), which may be attributable to malaria *per se* or to the ensuing pancreatitis. The index case also had multiorgan dysfunction syndrome (hypotension, ARDS, renal failure, thrombocytopenia, and liver failure). Further, our patient also developed abdominal compartment syndrome (seen in 11% of cases of pancreatitis of any cause).<sup>[25]</sup>

The index case suffered from severe pancreatitis (BISAP score of 4) with a predicted mortality of >15%.<sup>[26]</sup> Yet, he responded well to management with intravenous artesunate and doxycycline consistent with the results of the systematic review in which most reported cases had moderate to severe pancreatitis and responded favorably to antimalarial therapy [Table 2]. Four out of 22 (18.2%) patients died. Of the four patients, one patient did not receive antimalarial therapy (identified postmortem) while in one case, antimalarial therapy was started in the 2<sup>nd</sup> week of illness. This highlights the importance of the early institution of antimalarial therapy which along with nonsurgical management is usually associated with a favorable outcome.

## Conclusion

Malaria may rarely be complicated by pancreatitis. It is essential to suspect it clinically in patients with abdominal pain, to confirm it early, and to treat it appropriately to have a good outcome.

## Financial support and sponsorship

Nil.

## Conflicts of interest

There are no conflicts of interest.

## References

1. Dhingra N, Jha P, Sharma VP, Cohen AA, Jotkar RM, Rodriguez PS, *et al.* Adult and child malaria mortality in India: A nationally representative mortality survey. *Lancet* 2010;376:1768-74.
2. White NJ, Pukrittayakamee S, Hien TT, Faiz MA, Mokuolu OA, Dondorp AM. Malaria. *Lancet* 2014;383:723-35.
3. Srinivas R, Agarwal R, Gupta D. Severe sepsis due to severe falciparum malaria and leptospirosis co-infection treated with activated protein C. *Malar J* 2007;6:42.
4. Druml W, Laggner AN, Lenz K, Grimm G, Schneeweiss B. Pancreatitis in acute hemolysis. *Ann Hematol* 1991;63:39-41.
5. Saruc M, Yuceyar H, Turkel N, Ozutemiz O, Tuzcuoglu I, Yuce G, *et al.* An experimental model of hemolysis-induced acute pancreatitis. *Braz J Med Biol Res* 2003;36:879-86.
6. Sonani R, Bhatnagar N, Maitrey G. Autoimmune hemolytic anemia in a patient with Malaria. *Asian J Transfus Sci* 2013;7:151-2.
7. Egdagl A. A review of 105 reported cases of acute pancreatitis, with special reference to aetiology: With report of two cases. *Johns Hopkins Med J* 1907;18:130-2.
8. Gurman G, Schlaeffer F, Alkan M, Heilig I. Adult respiratory distress syndrome and pancreatitis as complications of falciparum malaria. *Crit Care Med* 1988;16:205-6.
9. Sarma PS, Kumar RS. Abdominal pain in a patient with falciparum malaria. *Postgrad Med J* 1998;74:425-7.
10. Praetorius F, Altrock G, Brees N, Schuh N, Faulde M. Imported anopheles: In the luggage or from the airplane? A case of severe autochthonous malaria tropica near an airport. *Dtsch Med Wochenschr* 1999;124:998-1002.
11. Desai DC, Gupta T, Sirsat RA, Shete M. Malarial pancreatitis: Report of two cases and review of the literature. *Am J Gastroenterol* 2001;96:930-2.
12. Seshadri P, Dev AV, Viggesswarpu S, Sathyendra S, Peter JV. Acute pancreatitis and subdural haematoma in a patient with severe falciparum malaria: Case report and review of literature. *Malar J* 2008;7:97.
13. Kumar S, Jain AP, Vikas. Falciparum malaria presenting as acute pancreatitis. *J Vector Borne Dis* 2010;47:121-2.
14. Thapa R, Mallick D, Biswas B. Childhood *Plasmodium falciparum* malaria complicated by acute pancreatitis. *Trop Doct* 2010;40:184-5.
15. Mandal B, Das BK, Chatterjee SK, Guh P, Shai S, Sharma A, *et al.* Acute pancreatitis in a case of falciparum malaria – A rare presentation. *J Assoc Physicians India* 2011;59:731-3.
16. Mohapatra MK, Gupta MP. Falciparum malaria complicated with acute pancreatitis: A report of case series. *J Vector Borne Dis* 2011;48:177-9.
17. Sharma V, Sharma A, Aggarwal A, Bhardvaj G, Aggarwal S. Acute pancreatitis in a patient with vivax malaria. *JOP* 2012;13:215-6.
18. Atam V, Singh AS, Yathish BE, Das L. Acute pancreatitis and acute respiratory distress syndrome complicating *Plasmodium vivax* malaria. *J Vector Borne Dis* 2013;50:151-4.
19. Ghosh S, Das SK, Sharma A. Unusual presentation of acute pancreatitis in falciparum malaria. *Trop Parasitol* 2014;4:56-7.
20. Johnson RC, DeFord JW, Carlton PK. Pancreatitis complicating falciparum malaria. *Postgrad Med* 1977;61:181-3.
21. Sharma S, Kant K. Acute pancreatitis – An unusual complication of falciparum malaria. *Indian J Med Case Rep* 2013;2:26-8.
22. Sundriyal D, Kumar N, Chandrasekharan A, Sharma B, Patnaik I, Kamble U. Fatal complications of *Plasmodium vivax* malaria: A series of three case reports. *Ann Trop Med Public Health* 2013;6:578-80.
23. Singh J, Dinkar A, Atam V, Atam I, Jitender S. An uncommon presentation of severe falciparum Malaria: Acute pancreatitis. *Int J Med Sci* 2014;2:26-8.
24. Badhal SS, Irshad M, Badhal S, Yadav K. Acute on chronic pancreatitis masking falciparum malaria: A case report. *Glob J Health Sci* 2009;1:123-5.
25. Geelenter G, Fahoum B, Gardezi S, Schein M. Abdominal compartment syndrome in severe acute pancreatitis: An indication for a decompressing laparotomy? *Dig Surg* 2002;19:402-4.
26. Singh VK, Wu BU, Bollen TL, Repas K, Maurer R, Johannes RS, *et al.* A prospective evaluation of the bedside index for severity in acute pancreatitis score in assessing mortality and intermediate markers of severity in acute pancreatitis. *Am J Gastroenterol* 2009;104:966-71.